

Anesthesia Case of the Month

Sponsored by the American College of Veterinary Anesthesiologists. Comments and contributions should be directed to Dr. Jeff C. H. Ko, Department of Medicine and Surgery, College of Veterinary Medicine, Oklahoma State University, Stillwater, OK 74078; telephone: 405/744-8584; e-mail: jeff_ko@okway.okstate.edu

History

A 2-year-old 5.0-kg (11.0-lb) spayed female domestic shorthair cat was admitted to the Louisiana State University Veterinary Teaching Hospital for an elective forepaw onychectomy. The cat's medical history was unremarkable, and no abnormalities were observed on physical examination. The results of a CBC, BUN concentration determination, and urinalysis were within reference range limits.

The cat received 2.0 mg of butorphanol tartrate (0.4 mg/kg [0.18 mg/lb] of body weight) and 0.15 mg of acepromazine maleate (0.03 mg/kg [0.014 mg/lb]) IM before surgery. Thirty minutes after administration of these drugs, a 22-gauge catheter was placed in a lateral saphenous vein, and 5.0 mg of propofol (1.0 mg/kg [0.45 mg/lb]) was administered slowly IV for induction of general anesthesia. A 4-mm internal diameter endotracheal tube was used for intubation, and anesthesia was maintained with halothane (0.5 to 2.0%) in oxygen (1 L/min) delivered through a pediatric circle system. An esophageal stethoscope and an ECG were used to monitor heart rate and rhythm.

Question

How could analgesia be enhanced in this cat?

Answer

In addition to general anesthesia and a systemic analgesic (butorphanol), a 4-point regional nerve block was performed on each forepaw by use of 0.5% bupivacaine hydrochloride to provide additional analgesia to the digits. Digital cutaneous and articular sensory innervation of the forepaw in cats is provided by the dorsal and palmar digital nerves, which arise from the radial, median, and ulnar nerves (Table 1; Fig 1 and 2).¹ To properly perform the nerve blocks, anatomic landmarks were used to determine injection sites.

After the cat was determined to be at an adequate surgical plane of anesthesia, the halothane vaporizer setting was reduced incrementally while the response to surgical stimuli was monitored closely. Each distal phalanx was disarticulated with a No. 11 scalpel blade, and the unguis crest skin incisions were individually opposed with 3-0 chromic gut, using a single cruciate suture. The duration of the surgical procedure was 40

This report was submitted by P. Brendon Ringwood, DVM and Julie A. Smith, DVM, DACVA; from the Department of Veterinary Clinical Sciences, Louisiana State University, Baton Rouge, LA 70803.

minutes, and anesthesia was maintained with a halothane concentration of 0.5%. Recovery was smooth and uneventful. The cat was observed for signs of pain during the next 24 hours. An additional dose of butorphanol (2.0 mg) was administered 5 hours after surgery when the cat began to have signs of discomfort (eg, non-weight-bearing, shaking the forepaws, and restlessness). The cat was discharged 30 hours after the procedure.

Discussion

Elective onychectomy in cats, although controversial among veterinarians and the public, is a procedure that is commonly performed in private practices and teaching institutions. A variety of surgical procedures have been described,²⁻⁹ all of which result in substantial signs of pain in cats.¹⁰⁻¹⁴ Alleviation of signs of pain is a major consideration and an integral part of a balanced anesthetic protocol.^{2,10-11} Because of cost and time constraints, the need for controlled substances, and the reluctance to try new drugs, the provision of adequate analgesia is too commonly neglected for surgical patients in veterinary medicine.¹⁵ The cost- and time-effective technique described here can be readily incorporated for routine elective onychectomy management.

Signs of pain associated with surgical procedures are caused by an onslaught of nociceptive transmission that induces electrophysiologic and morphologic changes within the spinal cord. These changes cause a central sensitization or hyperexcitability of the nervous tissue that contributes to signs of pain much longer than the initial stimulus. The administration of a local anesthetic blockade prior to the painful event preemptively prevents the establishment of central sensitization, decreases the severity of signs of pain after surgery, and reduces the requirement for pain control after surgery.¹⁶⁻¹⁹ Lower dosages of other anesthetic and analgesic agents are needed when local anesthetic techniques are incorporated.¹⁸⁻¹⁹ The 4-point block performed on this cat provided preemptive analgesia during and after surgery.

Bupivacaine was selected for its long duration of effect (4 to 6 hours) relative to other local anesthetics such as lidocaine (1 to 2 hours).¹⁹ A disadvantage of

Table 1—Digital sensory innervation of the forepaw in cats.

Area	Nerves
Dorsal cutaneous sensation	Radial nerve (lateral and medial superficial branch) Ulnar nerve (dorsal branch)
Palmar cutaneous sensation	Median nerve Ulnar nerve (superficial and deep palmar branches)
Digital joints	Ulnar nerve (superficial and deep palmar branches)

Notice that information in the table refers to the origins of the dorsal and palmar digital nerves, which arise from branches of the median, ulnar, and radial nerves¹

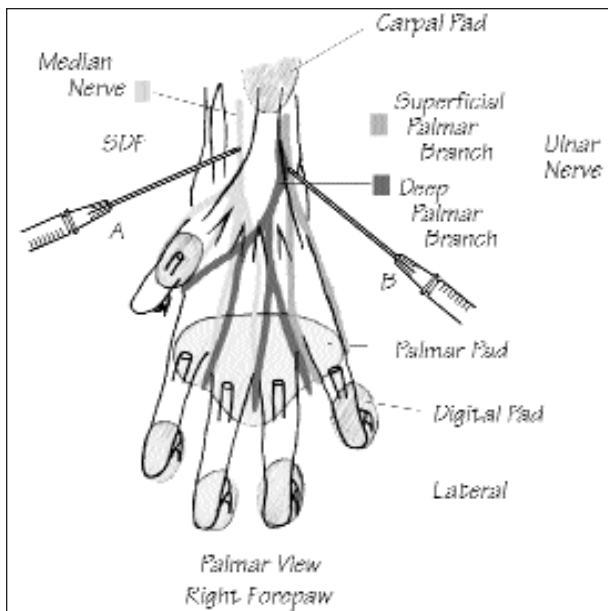


Figure 1—Diagram of the palmar view of the right forepaw of a cat depicting sensory innervation and anatomic landmarks for the 4-point digital nerve block. Nerve block A—the superficial digital flexor (SDF) tendon provides the landmark for location of the median nerve and superficial and deep palmar branches of the ulnar nerve. The carpus is fully extended, and the SDF tendon is palpated along the palmar aspect of the paw. The median nerve is blocked just medial to the SDF tendon at a point approximately a third of the distance (distally) between the carpal pad and the first digital pad with 0.15 ml of bupivacaine hydrochloride. Nerve block B—the palmar branches of the ulnar nerve are blocked along the lateral aspect of the SDF tendon at approximately the same level (distally) as the median nerve block with 0.15 ml of bupivacaine.

bupivacaine is the time to effect (15 to 20 minutes), compared with rapidly effective agents like lidocaine (5 minutes).²⁰ Onychectomy in cats is often performed in conjunction with other elective procedures, allowing plenty of time for the bupivacaine to take effect before declawing. If the onychectomy is to be performed alone, mixing lidocaine hydrochloride and bupivacaine (1:1) will provide rapid onset of action with the long duration of action. The effects of bupivacaine last well into the recovery period, which smooths recovery, increases patient comfort, and reduces the occurrence of early bandage removal by cats in response to pain.

Potential complications of any local anesthetic administration include infection, failure of blockade, or inadvertent IV injection.²¹ It is critical to aspirate prior to injection to ensure that the needle is not placed IV. Inadvertent IV administration of bupivacaine could result in cardiac dysrhythmias.²² The total overall dosage used for both paws should not exceed the toxic dosage of 5.0 mg/kg.²⁰ Butorphanol was used before surgery to smooth induction and to provide analgesia in the event that the block was incomplete or unsuccessful.

Ideally, nerve blocks should be performed, using aseptic techniques¹⁹; however, it is undesirable to shave the paws for onychectomy. The paws should be thoroughly cleaned and soaked with alcohol prior to the block. A sterile small-gauge needle should always be used. The needle may have to be changed between sites if it becomes dull. We have not seen infection resulting

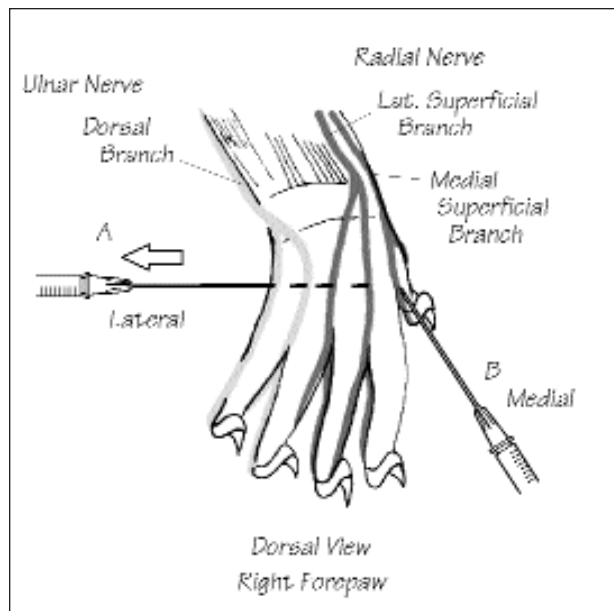


Figure 2—Diagram of the dorsal view of the right forepaw depicting sensory innervation and anatomic landmarks for the 4-point digital nerve block. Nerve block A—inserting the needle SC from lateral to medial, just distal to the carpus blocks dorsal digital nerves II to V. As the needle is withdrawn, a total of 0.2 ml of bupivacaine is injected. Care must be taken to ensure dorsal digital nerve V is blocked, as it runs laterally to (not dorsally to) metacarpal V. Nerve block B—dorsal digital nerve I (innervation to the first phalanx) is blocked by inserting the needle from distal to proximal to the level of the dorsal aspect of the articulation between metacarpal I and II and injecting 0.1 ml of bupivacaine, SC.

from the administration of the 4-point digital nerve block when paws ($n > 30$) were prepared in this manner.

The 4-point block used in this cat provided a safe technically easy time- and cost-effective method for the provision of analgesia before, during, and after elective onychectomy.

References

- Hudson LC, Hamilton WP. *Atlas of feline anatomy for veterinarians*. Philadelphia: WB Saunders Co, 1993:62–67, 214–217.
- Martinez SA, Hauptman J, Walshaw R. Comparing two techniques for onychectomy in cats and two adhesives for wound closure. *Vet Med* 1993;88:516–525.
- Tobias KS. Feline onychectomy at a teaching institution: a retrospective study of 163 cases. *Vet Surg* 1994;29:274–280.
- Weege J. Onychectomy in the cat using the White nail trimmer (a photographic essay). *Vet Med Small Anim Clin* 1974;69:194–195.
- Nagle AC. A technique for feline onychectomy. *Vet Med Small Anim Clin* 1976;71:1685–1687.
- Goodyear MD. A technique for onychectomy in the cat. *Vet Med Small Anim Clin* 1977;72:569–572.
- Woodring MW. Alternate procedure for onychectomy (in letters to the editor). *Vet Med Small Anim Clin* 1977;72:960.
- Rubin LD, Maplesden DC. A technique for declawing cats. *Vet Med Small Anim Clin* 1978;73:52–53.
- Pavlick M. Feline onychectomy: an alternative procedure. *Feline Pract* 1980;10:57–60.
- Ko JCH, Thurmon JC, Benson GC, et al. An alternative drug combination for use in declawing and castrating cats. *Vet Med* 1993;88:1061–1065.
- Morgan L. Pressure bandaging technique reduces complications at onychectomy site (in idea exchange). *Vet Med* 1997;92:857–858.
- American College of Veterinary Anesthesiologists' position paper on the treatment of pain in animals. *J Am Vet Med Assoc* 1998;213:628–630.
- Benson GJ, Wheaton LG, Thurmon JC, et al. Postoperative

catecholamine response to onychectomy in isoflurane-anesthetized cats: effects of analgesics. *Vet Surg* 1991;20:222–225.

14. Smith JD, Allen SW, Quandt JE, et al. Indicators of postoperative pain in cats and correlation with clinical criteria. *Am J Vet Res* 1996;57:1674–1678.

15. Lin HC, Benson GJ, Thurmon JC, et al. Influence of anesthetic regimens on the perioperative catecholamine response associated with onychectomy in cats. *Am J Vet Res* 1993;54:1721–1724.

16. Sackman JE. Pain: its perception and alleviation in dogs and cats. Part I. The physiology of pain. *Compend Contin Educ Pract Vet* 1991;13:71–79.

17. Winkler KP, Greenfield CL, Benson GJ. The effect of wound irrigation with bupivacaine on postoperative analgesia of the feline onychectomy patient. *J Am Anim Hosp Assoc* 1997;33:346–352.

18. Woolf CJ, Chong MS. Preemptive analgesia—treating postoperative pain by preventing the establishment of central sensitization. *Anesth Analg* 1993;77:362–379.

19. Pascoe P. Local and regional anesthesia and analgesia. *Semin Vet Med and Surg (Small Anim)* 1997;12:94–105.

20. Heaver JE. Local anesthetics. In: Thurman JC, Tranquilli WJ, Benson GJ, eds. *Lumb and Jones' veterinary anesthesia*. 3rd ed. Baltimore: The Williams & Wilkins Co, 1996;23:330–336.

21. Skarda RT. Local and regional anesthetic and analgesic techniques: horses. In: Thurman JC, Tranquilli WJ, Benson GJ, eds. *Lumb and Jones' veterinary anesthesia*. 3rd ed. Baltimore: The Williams & Wilkins Co, 1996;23:448–478.

22. Thompson SE, Johnson JM. Analgesia in dogs after intercostal thoracotomy. A comparison of morphine, selective intercostal nerve block, and interpleural regional analgesia with bupivacaine. *Vet Surg* 1991;20:73–77.