

# Dynamic tracheal collapse as a cause of exercise intolerance in a Thoroughbred

Joanne Tetens, DVM, MS, DACVS; Jeremy D. Hubert, BVSc; Alison L. Eddy, MA, DVM; Rustin M. Moore, DVM, PhD, DACVS

- ▶ Tracheal collapse in large animals occurs most commonly as a result of direct trauma.
- ▶ Tracheal collapse can limit athletic function by increasing airway impedance and turbulence, thereby increasing the work of breathing.
- ▶ When the cause of exercise intolerance cannot be determined in horses from endoscopic evaluation of the nasopharynx during rest and exercise, tracheal videoendoscopy should be performed during exercise.

A 2-year-old unraced Thoroughbred filly was admitted to the hospital for evaluation of exercise intolerance and superficial digital flexor tendonitis of the right forelimb. Respiratory noise was not observed by the trainer. Prior to admission, endoscopy of the nasopharynx was performed by the referring veterinarian, which revealed right arytenoid paresis.

On admission, routine physical examination of the respiratory system was unremarkable. Resting videoendoscopy (ie, while the horse was standing) of the upper respiratory tract (ie, nasopharynx, auditory tube diverticuli, and trachea) was performed. Mucus was observed near the opening of the right guttural pouch (ie, auditory tube diverticulum). Upon entrance into the right guttural pouch, a small amount of mucus was observed on the ventral surface of the medial compartment. There were no abnormalities associated with the left guttural pouch. Grade-III (on a scale of I to IV) pharyngeal lymphoid hyperplasia<sup>1</sup> and grade-III (on a scale of I to IV) right arytenoid paresis<sup>2</sup> were observed. Upon nasal occlusion and induction of swallowing, full abduction of the right arytenoid was not attained, and it fell into a paramedian position. Evaluation of the trachea revealed compression of the right dorsolateral aspect 100 cm distal to (midcervical) the external nares (Fig 1). Exudate in the tracheal lumen was not observed. On external palpation of the cervical portion of the trachea, no lesions were identified. We hypothesized that unobserved trauma to the midcervical region of the horse's neck may have caused the tracheal deformity and damage to the right recurrent laryngeal nerve, resulting in right arytenoid paresis.

Examination of the right forelimb revealed a palpable swelling involving the middle portion of the superficial digital flexor tendon. Ultrasonographic

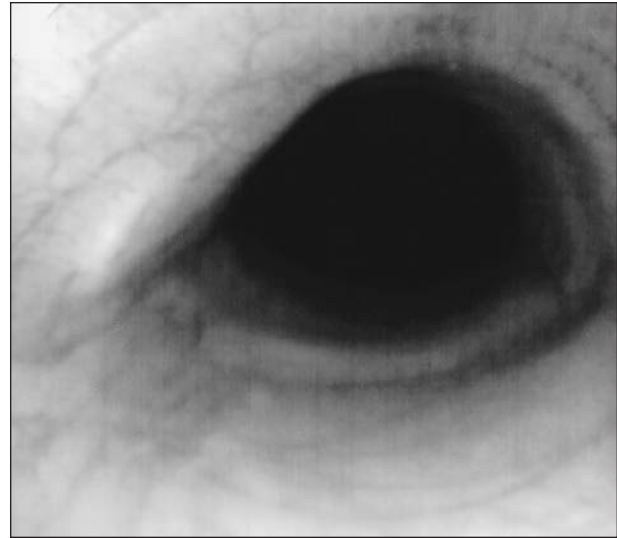


Figure 1—Videoendoscopic image of the midcervical region of the trachea of a horse while standing. Notice the deformity of the right dorsolateral portion of the tracheal cartilages.

examination revealed a grade-IV (on a scale of I to IV) lesion<sup>3</sup> located 18.8 cm distal to the accessory carpal bone that involved approximately 15% of the cross-sectional area of the superficial digital flexor tendon and extended 3 cm distally.

Because the horse had evidence of inflammatory airway disease and the exercise intolerance was not associated with respiratory stridor, medical management was elected; however, the potential for a right prosthetic laryngoplasty was discussed with the owner. Owing to the concurrent superficial digital flexor tendonitis, it was recommended that the horse be confined to a box stall with hand walking for 30 days, then swim for 30 days, and then return for ultrasonographic reevaluation of the tendon and further evaluation of the respiratory tract.

The horse was admitted to the hospital for follow-up examination 4.5 months later. Ultrasonographic examination of the right front superficial digital flexor tendon revealed complete resolution of the lesion. Resting videoendoscopic evaluation of the nasopharynx indicated that there was no change in right arytenoid function. Prior to returning the horse to training, the owner requested that dynamic videoendoscopy (ie, while the horse was exercising) be performed. The horse was conditioned to the high-speed treadmill, and dynamic videoendoscopy was performed 4 days after admission. The horse was unable to attain maximal speed because of lack of appropriate conditioning at time of admission and history of superficial digital flexor tendonitis. The right arytenoid obtained approxi-

From the Department of Veterinary Clinical Sciences, School of Veterinary Medicine, Louisiana State University, Baton Rouge, LA 70803-8410. Dr. Eddy's present address is the Department of Surgical and Radiological Sciences, School of Veterinary Medicine, University of California, Davis, CA 95616-8734.

mately 80% of maximal abduction and did not collapse into the airway during submaximal exertion. We recommended that the horse return to race training. If exercise intolerance or respiratory noise developed, the horse was to be returned for further evaluation during more intensive exercise on a treadmill.

The horse trained well until it reached racing speed, when it began to perform poorly. Six months after beginning training, the horse was admitted to the hospital for continued exercise intolerance. Resting videoendoscopic evaluation of the nasopharynx revealed grade-II pharyngeal lymphoid hyperplasia and grade-III right arytenoid paresis. Lateral laryngeal radiography was performed, which revealed no evidence of dystrophic ossification of the arytenoids and a thyroepiglottic length within reported reference range values for Thoroughbreds.<sup>4</sup> Although the prognosis for successful racing performance was not considered favorable, a right prosthetic laryngoplasty was recommended, owing to the horse's continued exercise intolerance and the owner's desire to race the horse.

Prior to surgery, results of CBC were within reference ranges. Preoperatively, potassium penicillin G (22,000 U/kg [10,000 U/lb] of body weight, IV, q 6 h), gentamicin sulfate (6.6 mg/kg [3 mg/lb], IV, q 24 h), and phenylbutazone (2.2 mg/kg [1 mg/lb], PO, q 12 h) were administered. During surgery, a routine laryngoplasty incision was performed over the right arytenoid cartilage. Upon evaluation, the muscular process was barely definable and located further dorsally than typical. A double strand of No. 5 suture material<sup>a</sup> was placed and tied tightly to abduct the right arytenoid. However, placement of the suture was difficult, and adequate purchase into the muscular process was not attained. The soft tissues were closed in routine fashion, and anesthetic recovery was uneventful.

Postoperative videoendoscopic evaluation revealed minimal abduction of the right arytenoid cartilage. The horse was maintained on antimicrobial agents for 48 hours and phenylbutazone for 12 days. The horse was discharged from the hospital 8 days after admission with instructions to the owner to continue stall rest for 7 days, followed by stall rest with hand walking for 3 weeks. After 4 weeks, the horse was to return to race training. If the exercise intolerance continued, a right partial arytenoidectomy would be considered.

Three months after surgery, the horse returned for evaluation of continued exercise intolerance. Physical examination findings, including vital measurements and thoracic auscultation, were unremarkable. Resting videoendoscopic evaluation of the nasopharynx and trachea revealed that the right arytenoid was located in a paramedian position. There was a large amount of mucopurulent exudate with small quantities of feed material observed on the ventral surface of the trachea. A transtracheal aspirate was collected via the endoscope. Cytologic analysis of the fluid revealed rare RBC with a nucleated cell population that consisted predominantly of uniform columnar epithelial cells, with few scattered neutrophils and goblet cells. A moderate amount of mucus was observed in the background. Several bacteria-covered squamous cells were observed. The cytologic interpretation was mild neu-

trophilic inflammation. Results of bacterial culture and antimicrobial susceptibility testing revealed a pure growth of *Pasteurella* spp, which was susceptible to all antimicrobial agents tested. The horse was discharged from the hospital the same day with instructions to the owner to administer trimethoprim-sulfamethoxazole (15 mg/kg [7 mg/lb], PO, q 12 h) and clenbuterol (4.5 mg, PO, q 12 h) for 7 days. The horse was to return for reevaluation and dynamic videoendoscopic evaluation in 10 days.

Thirteen days later, the horse returned for reevaluation. Resting videoendoscopic evaluation revealed resolution of exudate in the trachea. Dynamic videoendoscopic evaluation during maximal exercise revealed the right arytenoid to be fixed in a submaximal position with no evidence of collapse into the airway. Bilateral axial deviation of the aryepiglottic folds occurred. The horse made a loud inspiratory noise during exercise. The amount of respiratory noise did not appear to be compatible with the amount of laryngeal dysfunction that was observed. Because of the tracheal deformity that was identified on initial admission, it was decided that dynamic videoendoscopy with the endoscope positioned in the midcervical tracheal region would be performed the following day. Dynamic tracheal videoendoscopic evaluation revealed marked tracheal collapse, which occurred during inspiration, resulting in at least 70% narrowing of the lumen in a dorsoventral direction for a distance of approximately 10 cm (Fig 2). The horse was retired from race training owing to the extent of the tracheal collapse.

Tracheal collapse has been described in horses, miniature horses, and ponies.<sup>5-7</sup> Acute or chronic tracheal abnormalities may be secondary to peritracheal abscesses,<sup>6,8</sup> tumors,<sup>9</sup> postoperative complications from tracheotomies,<sup>10</sup> abnormalities of cartilage rings,<sup>7,11</sup> pneumonia,<sup>12</sup> or any injury causing cartilage ring trauma.<sup>8,10</sup> Tracheal collapse in large animals occurs most

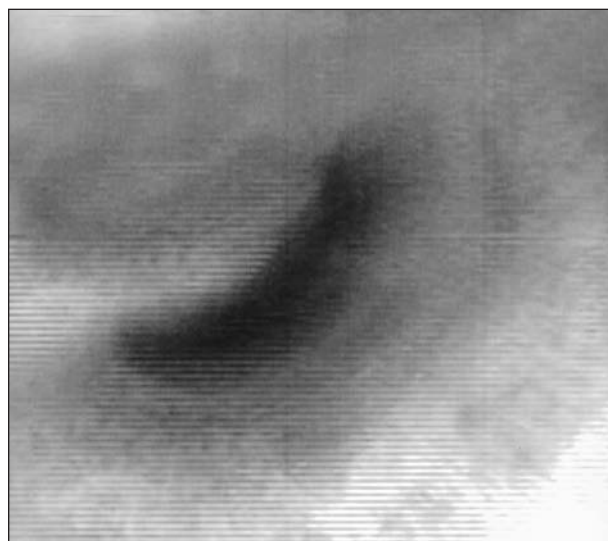


Figure 2—Videoendoscopic image (digitally enhanced) of the midcervical region of the trachea while exercising. Notice the right dorsolateral compression of the trachea resulting in 71% reduction in the dorsoventral cross-sectional diameter during inspiration.

commonly as a result of direct trauma, with the cranial and midcervical portions of the trachea being most susceptible, owing to its superficial location.<sup>13-15</sup>

Rigidity of the trachea is provided by hyaline cartilage rings, which are incomplete dorsally.<sup>16</sup> The dorsal surface of the trachea is bridged by connective tissue and the trachealis muscle.<sup>16</sup> Tracheal cartilage prevents collapse during inhalation when tracheal luminal pressures are lower than atmospheric pressure.<sup>16</sup> Tracheal collapse can critically limit athletic function by increasing airway impedance and turbulence, thereby increasing the work of breathing.<sup>17</sup>

Laryngeal paralysis associated with tracheal collapse has been described in horses secondary to a congenital malformation<sup>18</sup> and secondary to recurrent laryngeal nerve involvement in a peritracheal abscess.<sup>6</sup> In the midcervical region, the recurrent laryngeal nerves lie on the dorsolateral surface of the trachea as they pass rostrally.<sup>19</sup> In the horse of our report, the tracheal deformity was located on the right dorsolateral aspect of the midcervical region, which is a location similar to the right recurrent laryngeal nerve. Therefore, unobserved blunt trauma to the midcervical region in this horse may have led to right recurrent laryngeal nerve damage and subsequent right arytenoid paresis.

Because right arytenoid and cricoid cartilage deformities were identified at surgery, congenital malformation of these structures cannot be ruled out as the cause of right arytenoid paresis. Congenital right-sided laryngeal cartilage malformation usually occurs in Thoroughbreds.<sup>20</sup> The right arytenoid is incapable of full abduction but maintains a position that is approximately 80 to 90% abducted (resting, grade III).<sup>20</sup> The estimated degree of right arytenoid abduction attained by the horse in this report was 80%. The precise cause (recurrent laryngeal nerve damage or congenital cartilage malformation) of the right-sided paresis could not be determined in this horse.

Treatment of tracheal collapse depends on etiologic factors, the length of trachea involved, and accessibility of the affected tracheal segment.<sup>9</sup> Treatment options include complete replacement with prostheses,<sup>21</sup> placement of external prostheses to stent collapsed rings,<sup>10</sup> plication of the trachealis muscle,<sup>22</sup> and tracheal resection and anastomosis.<sup>23</sup> In addition, chondrotomy allows remodeling of deformed tracheal rings, which can then be anchored to an extraluminal prosthesis.<sup>10,16</sup> Because of the extent of the tracheal collapse, the potential postoperative complications associated with surgical procedures of the trachea, and the owner's willingness to use the horse for reproductive purposes, surgical intervention was not attempted.

In this horse with dynamic tracheal collapse, clinically apparent respiratory compromise occurred only with intensive exercise when inspiratory tracheal pressure was markedly negative. The tracheal collapse may have been exacerbated by axial deviation of the aryepiglottic folds, which could further lower inspiratory tracheal pressure. The condition was not apparent

on resting or dynamic videoendoscopic evaluations with the endoscope positioned in the nasopharynx. Therefore, the use of dynamic tracheal videoendoscopic evaluation was important in making the diagnosis of tracheal collapse in this horse.

<sup>a</sup>Polydex, Deknatel Inc, Queens Village, NY.

## References

1. Raker C. The pharynx. In: Mannsman R, McAllister E, eds. *Equine medicine and surgery*. 3rd ed. Santa Barbara, Calif: American Veterinary Publications Inc, 1982;747-750.
2. Hackett R, Ducharme N, Fubini S, et al. The reliability of endoscopic examination in assessment of arytenoid cartilage movement in horses Part I: Subjective and objective laryngeal evaluation. *Vet Surg* 1991;20:174-179.
3. Genovese R, Rantanen N, Simpson B. The use of ultrasonography in the diagnosis and management of injuries of the equine limb. *Compend Contin Educ Pract Vet* 1987;9:945-955.
4. Tulleners E. Correlation of performance with endoscopic and radiographic assessment of epiglottic hypoplasia in racehorses with epiglottic entrapment corrected by use of contact neodymium:yttrium aluminum garnet laser. *J Am Vet Med Assoc* 1991;198:621-626.
5. Martin J. Dorsoventral flattening of the trachea in a pony. *Equine Pract* 1981;3:17-22.
6. Riggs DL, Ramey DW, Reinertson EL. Tracheal compression secondary to abscessation of cranial mediastinal lymph nodes in a horse. *J Am Vet Med Assoc* 1985;186:283-284.
7. Simmons T, Petersen M, Parker J, et al. Tracheal collapse due to chondrodysplasia in a miniature horse foal. *Equine Pract* 1988;10:39-42.
8. Randall R, Myers V. Partial tracheal stenosis in a horse. *Vet Med Small Anim Clin* 1973;68:264-266.
9. Yovich J, Stashak T. Surgical repair of a collapsed trachea caused by a lipoma in a horse. *Vet Surg* 1984;13:217-221.
10. Robertson TJ, Spurlock GH. Tracheal reconstruction in a foal. *J Am Vet Med Assoc* 1986;189:313-314.
11. Mair T, Lane J. Tracheal obstructions in two horses and a donkey. *Vet Rec* 1990;126:303-304.
12. Fenger CK, Kohn CW. Tracheal obstruction from tracheal collapse associated with pneumonia in a horse. *J Am Vet Med Assoc* 1992;200:1698-1700.
13. Horney FD. Tracheal prosthesis in a calf. *J Am Vet Med Assoc* 1975;167:463-464.
14. Boyd C, Hanselka D. Prosthesis for correction of collapsed trachea. *J Am Anim Hosp Assoc* 1976;12:829-830.
15. Siger L, Hawkins J, Andrews F, et al. Tracheal stenosis and collapse in horses. *Compend Contin Educ Pract Vet* 1998;20:628-636.
16. Shappell K. Trachea. In: Auer J, Stick J, eds. *Equine surgery*. Philadelphia: WB Saunders Co, 1999;376-381.
17. West J. Mechanics of breathing. In: West J, ed. *Respiratory physiology—the essentials*. Baltimore: The Williams & Wilkins Co, 1981;86-113.
18. Hanselka D. Tracheal collapse and laryngeal hemiplegia in the horse (a case report). *Vet Med Small Anim Clin* 1973;68:859-862.
19. Quinlan T, Goulden B, Barnes G, et al. Innervation of the equine intrinsic laryngeal muscles. *N Z Vet J* 1982;30:43-45.
20. Tulleners E, Stick J. Laryngoplasty and repeat laryngoplasty. In: White N, Moore J, eds. *Current techniques in equine surgery and lameness*. 2nd ed. Philadelphia: WB Saunders Co, 1998;137-142.
21. Carrig C, Groenendyk S, Seawright A. Dorsoventral flattening of the trachea in a horse and its attempted surgical correction: a case report. *J Am Vet Rad Soc* 1973;14:32-36.
22. Delahanty DD, Georgi JR. A tracheal deformity in a pony. *J Am Vet Med Assoc* 1954;125:42-44.
23. Tate LP, Koch DB, Sembrat RF, et al. Tracheal reconstruction by resection and end-to-end anastomosis in the horse. *J Am Vet Med Assoc* 1981;178:253-258.