

Changes in synovial fluid biomarker concentrations following arthroscopic surgery in horses with osteochondritis dissecans of the distal intermediate ridge of the tibia

Palle Brink DVM

Roger K. W. Smith DVM, PhD

Aage Tverdal PhD

Nils I. Dolvik DVM, PhD

Received November 23, 2013.

Accepted December 12, 2014.

From Jägersro Equine Clinic, Jägersrovägen 160, 212 37 Malmö, Sweden (Brink); the Royal Veterinary College, University of London, North Mymms, Hatfield, Hertfordshire, AL9 7TA, England (Smith); the Norwegian Institute of Public Health, Division of Epidemiology, Box 4404, Nydalen, 0403 Oslo, Norway (Tverdal); and the Department of Companion Animals, Norwegian School of Veterinary Science, 0033 Oslo, Norway (Dolvik).

Address correspondence to Dr. Brink (palle.brink@email.dk).

OBJECTIVE

To quantify concentrations of cartilage oligomeric matrix protein (COMP) and fibromodulin in synovial fluid from the tarsocrural joints (TCJs) of horses with osteochondritis dissecans (OCD) of the distal intermediate ridge of the tibia and determine whether concentrations would change following arthroscopic removal of osteochondral fragments.

ANIMALS

115 client-owned horses with OCD of the TCJ and 29 control horses euthanized for unrelated reasons.

PROCEDURES

COMP and fibromodulin concentrations were measured in synovial fluid from the TCJs of the affected horses before and after osteochondral fragments were removed arthroscopically and in synovial fluid from the TCJs of the control horses after euthanasia. Synovial biopsy specimens from the TCJs of affected and control horses were examined histologically for evidence of inflammation.

RESULTS

Synovial fluid COMP and fibromodulin concentrations prior to surgery in horses with OCD were not significantly different from concentrations in control horses. Fibromodulin, but not COMP, concentration in horses with OCD was significantly decreased after surgery, compared with the concentration before surgery. Fibromodulin concentration was significantly correlated with joint effusion score but not with lameness score or results of a flexion test and was correlated with histologic score for number of synoviocytes on the surface of the synovium but not with score for degree of infiltration of inflammatory cells in the synovium. Synovial fluid COMP concentration was not significantly correlated with clinical or histologic findings.

CONCLUSIONS AND CLINICAL RELEVANCE

Results suggested that fibromodulin, but not COMP, could potentially be a biomarker of joint inflammation in horses with OCD of the TCJ. (*Am J Vet Res* 2015;76:599–607)

Osteochondritis dissecans of the TCJ is common in young horses. Although this condition can result in clinical signs of joint inflammation¹ (eg, joint effusion and lameness), some affected horses do not develop clinical signs. Histologic examination of the synovium of affected joints can provide quantitative and qualitative measurements of the severity of joint inflammation in horses with OCD of the TCJ.² However, histologic evaluation of the synovium necessitates surgery to obtain a biopsy specimen, and the severity of synovial inflammation does not always correlate with the severity of clinical signs.² Furthermore,

although removal of osteochondral fragments, the treatment of choice for horses with OCD of the TCJ, usually resolves the associated lameness, it does not always diminish joint effusion.¹ Consequently, developing a minimally invasive procedure as an indicator of clinical progression and prognosis in affected horses would be beneficial.

Several molecular biomarkers in the synovial fluid of horses and humans have been investigated as potential indicators of the severity of joint inflammation.^{3–8} One such putative marker is COMP, a noncollagenous, homopentameric protein belonging to the thrombospondin family that has 5 globular domains attached to a central assembly domain by flexible strands.^{9,10} It is found almost exclusively in the extracellular matrix of tissues that function to resist load^{11–14} and is thought to be important for the formation and stabil-

ABBREVIATIONS

COMP Cartilage oligomeric matrix protein
OCD Osteochondritis dissecans
TCJ Tarsocrural joint

ity of the extracellular matrix.^{15,16} Cartilage oligomeric matrix protein is able to bind fibronectin and fibrillar collagens types I, II, and IX¹⁷⁻¹⁹ and is thought to contribute to the organization of the collagen fibrils into networks by maintaining fibril diameter and orientation.^{17,18} Cartilage oligomeric matrix protein, in association with granulins-epithelin precursor, may also be required for proliferation of chondrocytes²⁰ and may play an important role as a factor secreted by chondrocytes to ameliorate breakdown of matrix in arthritic joints.^{6,10,21,22} Cartilage oligomeric matrix protein is an ideal candidate as a biomarker of pathological cartilage lesions because it is abundant in cartilage yet is present only in low concentrations in the synovium.¹¹ Studies^{3,10,23-25} have demonstrated that its concentration in cartilage changes with a variety of conditions, including age, osteoarthritis, OCD, and joint sepsis, although not always in the same way in all species that have been studied. For instance, the concentration of COMP in synovial fluid has been shown to decrease with osteoarthritis in horses,^{3,4} but in humans, the concentration increases early in the course of osteoarthritis, then decreases as the disease becomes chronic and most of the cartilage in the joint has been lost.^{6,7} Concentrations of COMP also vary with age, breed, use, athletic activity, and type of joint.^{3,11-14,24,26,27}

Fibromodulin is an acidic 59-kDa protein²⁸ and a member of the leucine-rich, repeat proteoglycans family of matrix proteins.²⁹⁻³¹ Its concentration has been shown to be increased in the synovial fluid of osteoarthritic joints of humans, making it an early marker of joint inflammation and cartilage degradation.^{29,30} It interacts with collagen types I and II^{7,32,33} and is present on collagen fibers in cartilage and other connective tissues^{7,33} and, thus, is not specific to cartilage. Fibromodulin has been identified in the synovium of rabbits³⁴ and the articular cartilage matrix of pigs.³⁵ Fibromodulin is also bound in the extracellular matrix of articular cartilage to trappin-2, a small, serine protease inhibitor protein that may be important in the natural defense against serine protease-mediated damage of cartilage in the early stages of osteoarthritis.³⁶ Fibromodulin is thought to play an important role in the formation of collagen fibers^{8,32-34} and the tensile properties of the collagen network in articular cartilage.⁷ Fibromodulin has been shown to activate both the classical and alternative pathways of the complement system²⁹ and, therefore, might be a useful indicator of early signs of inflammation and osteoarthritis.^{7,30}

The primary purpose of the study reported here was to quantify concentrations of COMP and fibromodulin in synovial fluid from the TCJs of healthy horses and horses with naturally occurring OCD to determine whether these molecules would be useful biomarkers of joint inflammation. Secondary purposes were to determine whether concentrations varied with age of the horse, severity of clinical signs of inflammation (eg, lameness and effusion), or histologic appearance of the synovial membrane and, in particular, to determine whether concentrations would

change following arthroscopic removal of osteochondral fragments.

Materials and Methods

The study population consisted of 115 client-owned horses < 10 years of age that underwent arthroscopy for treatment of OCD of the distal intermediate ridge of the tibia involving 1 or both TCJs (total, 163 joints). None of the horses had received any intra-articular medications during the 3 months prior to surgery, according to the owners. All horses were evaluated at the Helsingborg Equine Hospital between October 2001 and March 2005. For each horse, sex, breed, age, and affected limbs were recorded. All study procedures were approved by the Swedish Animal Research Board.

Clinical evaluation

For each horse, the degree of effusion in affected joints (scored on a scale from 0 to 4), the degree of lameness on the affected limbs at a trot, and the results of a flexion test (sustained flexion for 1 minute) performed on each pelvic limb were scored preoperatively by one of the authors (PB).^{37,38} For horses that were lame, 10 mL of 2% mepivacaine^a was injected into the affected TCJ (with owner consent) to confirm that the joint was the source of the lameness. Horses with OCD of the distal intermediate ridge of the tibia that were not lame before or after the flexion test were eligible for inclusion in the study. Radiography of both tarsi was used to confirm the diagnosis of OCD of the distal intermediate ridge of the tibia. Horses were retained in the study if they had OCD of the medial malleolus of the tibia in addition to OCD of the distal intermediate ridge of the tibia.

Surgery

For all 115 horses, surgery was performed by a single individual (PB). Horses were anesthetized and positioned in dorsal recumbency, and approximately 10 mL of synovial fluid was collected by means of synoviocentesis of the distal aspect of the dorsomedial pouch of the TCJ with a 21-gauge needle. Saline (0.9% NaCl) solution was then infused into the joint, and arthroscopy was performed. Osteochondral fragments of the distal intermediate ridge of the tibia were removed, and exposed subchondral bone was debrided arthroscopically. Fragments present at the distal aspect of the medial malleolus were also removed, and subchondral bone was curetted. Finally, in 93 of the 115 (81%) horses (134 joints), a synovial biopsy specimen was obtained with a Ferris-Smith rongeur from the capsular fold directly opposite the distal intermediate ridge of the tibia (because of limitations in the research budget, biopsy specimens were obtained from only the first 134 joints). Specimens were fixed in buffered 5% formaldehyde^b within 20 minutes after sampling. Synovial fluid was centrifuged at 1,000 X g for 15 minutes within 30 minutes after collection; the supernatant was removed and stored at -20°C until assayed.

Follow-up

Postoperative rehabilitation included 2 weeks of stall confinement, followed by 4 weeks of walking, either in hand or on a horse walker or treadmill, along with turnout alone in a small paddock (approx 5 X 10 m). Trainers were instructed to gradually return the horse to its usual level of training after this time and to have the horse examined 6 months after surgery by one of the authors (PB) to determine the effect of surgery on degree of lameness and severity of joint effusion.

Overall, 79 of the 115 (69%) horses (113 joints) were returned approximately 6 months after surgery for follow-up examination. For 73 of these 79 horses (105 joints), synoviocentesis was performed at the time of the postsurgical physical examination, with approximately 5 mL of synovial fluid collected from the TCJ for analysis. The synovium was not biopsied.

Control horses

Twenty-nine horses < 10 years of age that were euthanized at the Helsingborg Equine Hospital between March 8, 2002, and May 14, 2004, for reasons unrelated to the present study were included as controls. Horses were not included if they had signs of systemic disease or gross evidence of TCJ abnormalities during necropsy.

For the control horses, a synovial fluid sample was collected following euthanasia from the uppermost TCJ by means of synoviocentesis of the distal aspect of the dorsomedial pouch of the joint. A small arthrotomy was then performed, and a synovial biopsy specimen was obtained with a Ferris-Smith rongeur from the capsular fold directly opposite the distal intermediate ridge of the tibia. Synovial fluid samples and synovial biopsy specimens were handled as described for the horses with OCD. All synovial fluid samples and synovial biopsy specimens were collected by a single individual (PB). All carcasses were refrigerated (5°C) until samples were collected, and time between death and collection of samples was recorded. Following collection of samples, an arthrotomy was performed to check for gross abnormalities of the TCJ.

Synovial fluid analysis

Synovial fluid COMP concentrations were determined by means of a homologous inhibition ELISA, as described by Smith et al.³⁹ Briefly, aliquots (115 µL) of synovial fluid samples (diluted 1:2,000) were mixed in triplicate with anti-equine COMP polyclonal antiserum (115 µL) diluted 1:40, and the resulting mixtures were incubated in sterile 96-well Petri dishes^c overnight in a humidified chamber at room temperature (approx 22°C). The polyclonal antiserum was obtained by injecting a rabbit with equine COMP purified from equine tendon and has been shown in previous studies^{3,11,39} to recognize intact and fragmented COMP.^{3,11,39} The following day, mixtures were transferred to 96-well ELISA plates^d coated with purified equine COMP

(0.1 µg/mL), blocked with bovine serum albumin, and incubated for 1 hour in a humidified chamber at room temperature. A secondary detection antibody (45 µL of alkaline phosphatase-conjugated swine anti-rabbit IgG^e [diluted 1:1,000]) was then added to each well, and plates were incubated for 1 hour in a humidified chamber at room temperature. Wells were washed, *p*-nitrophenyl phosphate (1 mg/mL) was added, and a zero-time absorption reading at 405 nm was obtained with an ELISA reader.^f The plates were then incubated for an additional 1 hour at room temperature, with gentle shaking, and a second reading was taken to provide a 2-point kinetic measurement based on increase in absorbance. Synovial fluid COMP concentration was then calculated by comparison, with the aid of cubic spline curve-fitting software, to results for a standard curve created with serial dilutions of purified COMP. The mean value of triplicate samples was used for statistical analyses. The assay was repeated with appropriately diluted samples if absorption was not within the appropriate range of the standard curve. The parallel nature of the inhibition curves was confirmed by testing various dilutions of synovial fluid ranging from 1:250 to 1:8,000.

Synovial fluid fibromodulin concentrations were determined by use of the same inhibition ELISA technique, except that a synovial fluid dilution of 1:40 was used, wells were coated with purified equine fibromodulin (0.25 µg/mL), and samples were incubated with anti-equine fibromodulin polyclonal antiserum diluted 1:1,500.³⁹ The parallel nature of the inhibition curves was confirmed by testing various dilutions of synovial fluid ranging from 1:5 to 1:5,120.

Synovial fluid total protein concentrations were determined with a handheld refractometer.

Histologic examination of synovial biopsy specimens

Synovial biopsy specimens were examined histologically by 2 individuals in a blinded fashion. Degree of infiltration of inflammatory cells and number of synoviocytes on the surface of the synovium were scored according to previously reported scoring systems.² For degree of infiltration of inflammatory cells, scores of 0 (no inflammation; only few scattered cells), 1 (mild inflammation; small number of cells), 2 (moderate inflammation; scattered areas with accumulation of cells), or 3 (severe inflammation; large areas with diffuse infiltration of cells) were assigned. For number of synoviocytes on the surface of the synovium, scores of 0 (no proliferation; single layer of cells), 1 (mild proliferation; 1 to 2 layers of cells), 2 (moderate proliferation; 3 to 4 layers of cells), or 3 (severe proliferation; ≥ 5 layers of cells) were assigned.

Statistical analysis

Synovial fluid concentrations of COMP and fibromodulin before and after arthroscopic removal of osteochondral fragments were analyzed by means of

multiple regression with a cluster option to account for horses in which both TCJs were affected. Similarly, synovial fluid COMP and fibromodulin concentrations were analyzed to detect associations with breed, sex, and age of the horses. Scores for lameness severity and severity of joint effusion were analyzed by means of multiple regression. Again, because joint was the unit of analysis, the cluster option was used to account for dependencies within horses. Agreement of histologic scores assigned by the 2 examiners was analyzed by use of the weighted κ method to control for discrepancies in differences between ordered categories. Mean scores for degree of infiltration of inflammatory cells and number of synoviocytes on the surface of the synovium values were then calculated and compared with clinical signs (ie, scores for severity of lameness and joint effusion) by use of multiple regression with the cluster option.² The effects of dilution associated with synovial effusion were accounted for by calculating the fibromodulin-to-COMP concentration ratio. Concentrations of total protein, COMP, and fibromodulin in synovial fluid obtained from the TCJs of horses with OCD before and after surgery were compared with each other and with concentrations for control horses by means of linear regression. The distribution of sampling time after euthanasia of the control horses was skewed to the right; therefore, data were log-transformed to approach a symmetric distribution. The Shapiro-Wilk test statistic (W), which is a test of normal distribution with values between 0 and 1, became 0.88 after transformation. Linear regression was performed with fibromodulin or COMP concentration as the dependent variable and time after euthanasia and age as independent variables. The effect of time between arthroscopy and follow-up examination was examined by means of multiple linear regression with change in score as the dependent variable and time since surgery (after log-transformation of the data) as the independent variable. Because there was no significant difference between horses with OCD of both the medial malleolus and the distal intermediate ridge of the tibia and horses with OCD of the distal intermediate ridge of the tibia alone, these groups were combined for analysis.

All analyses were performed with standard software.⁸ Values of $P \leq 0.05$ were considered significant.

Results

For the 115 horses with OCD, mean \pm SD age was 3.73 ± 1.84 years. Eighty-nine of the 115 (77%) horses were 1 to 3 years old, 21 (18%) were 4 to 6 years old, and the remaining 5 (4%) were 7 to 9 years old. For the 29 control horses, mean \pm SD age was 4.21 ± 2.16 years; 12 (41%) were 1 to 3 years old, 12 (41%) were 4 to 6 years old, and 5 (17%) were 7 to 9 years old. Of the 115 horses with OCD, 39 (34%) were stallions, 25 (22%) were geldings, and 51 (44%) were females. Of the 29 control horses, 7 (24%) were stallions, 11 (38%) were geldings, and 11 (38%) were females. Age

differed significantly between the 2 groups ($P < 0.01$), whereas sex distribution did not ($P = 0.19$).

Synovial fluid COMP and fibromodulin concentrations

For the 115 horses (163 joints) with OCD, mean \pm SD synovial fluid COMP and fibromodulin concentrations prior to surgery were 49.4 ± 25.9 $\mu\text{g/mL}$ and 6.6 ± 8.0 $\mu\text{g/mL}$, respectively. For the 29 control horses (29 joints), mean \pm SD COMP and fibromodulin concentrations were 59.8 ± 46.4 $\mu\text{g/mL}$ and 9.5 ± 14.1 $\mu\text{g/mL}$, respectively. Synovial fluid COMP ($P = 0.11$) and fibromodulin ($P = 0.20$) concentrations were not significantly different between these groups (Figure 1). Mean time between death and collection of synovial fluid samples from the control horses was 385 minutes. Time between death and sample collection was not significantly associated with synovial fluid COMP or fibromodulin concentration.

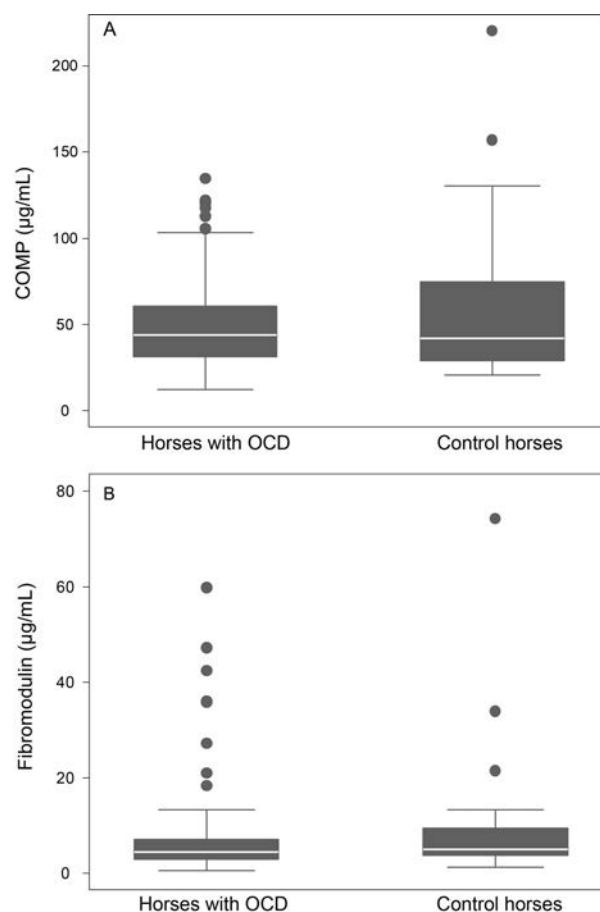


Figure 1—Box plots of COMP (A) and fibromodulin (B) concentrations in synovial fluid collected prior to surgery from 115 horses (163 joints) with OCD of the distal intermediate ridge of the tibia and from 29 control horses (29 joints) without abnormalities of the TCJ. For each plot, the black box represents the 25th to 75th percentiles, and the white line represents the median. Whiskers represent the 25th percentile $- 1.5 \times$ the interquartile range (75th percentile minus 25th percentile) and the 75th percentile $+ 1.5 \times$ the interquartile range. Circles represent outliers.

Effect of age

For horses with OCD, there was not a significant ($P = 0.14$) correlation between age and synovial fluid COMP concentration prior to surgery ($n = 163$ joints), but there was a significant ($P = 0.01$) negative correlation at the time of follow-up examination ($n = 105$ joints; **Figure 2**). A similar pattern was present between age and synovial fluid fibromodulin concentration (not significant [$P = 0.35$] prior to surgery [$n = 163$ joints] and significant [$P = 0.01$] at follow-up examination [105 joints]).

Effect of joint effusion

Both prior to surgery and at the time of follow-up examination, joint effusion score (potential scores ranged from 0 to 4) was significantly ($P = 0.004$) positively correlated with synovial fluid fibromodulin concentration in horses with OCD (**Figure 3**), but synovial fluid COMP concentration was not significantly correlated with joint effusion score at either time. Neither COMP nor fibromodulin concentration was significantly correlated with lameness score or with results of a flexion test. The fibro-

modulin-to-COMP concentration ratio was significantly ($P = 0.001$) correlated with joint effusion score.

Effect of surgery on COMP and fibromodulin concentrations

For the 73 horses (105 joints) that underwent synoviocentesis at the time of follow-up examination approximately 6 months after surgery, synovial fluid fibromodulin concentration (mean \pm SD, 3.8 ± 3.0 $\mu\text{g}/\text{mL}$) was significantly ($P < 0.001$) lower than the concentration prior to surgery (7.0 ± 8.9 $\mu\text{g}/\text{mL}$; **Figure 4**). In contrast, synovial fluid COMP concentration after surgery (52.2 ± 27.9 $\mu\text{g}/\text{mL}$) was not significantly ($P = 0.20$) different from concentration before surgery (50.0 ± 26.8 $\mu\text{g}/\text{mL}$). The fibromodulin-to-COMP concentration ratio was significantly ($P < 0.001$) lower after surgery than before surgery.

Correlation with total protein concentration in synovial fluid

For the control horses, synovial fluid total protein concentration was not significantly correlated with syno-

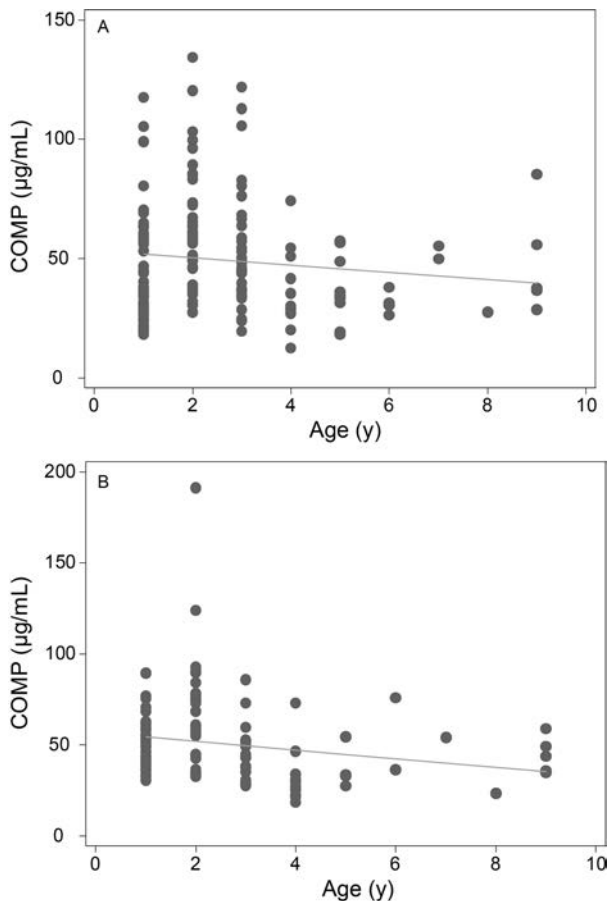


Figure 2—Scatterplots of age versus COMP concentration in synovial fluid collected prior to surgery from 115 horses (163 joints) with OCD of the TCJ (A) and from 73 of the horses (105 joints) at the time of follow-up examination approximately 6 months after arthroscopic removal of osteochondral fragments (B). In each graph, the solid line represents the linear regression.

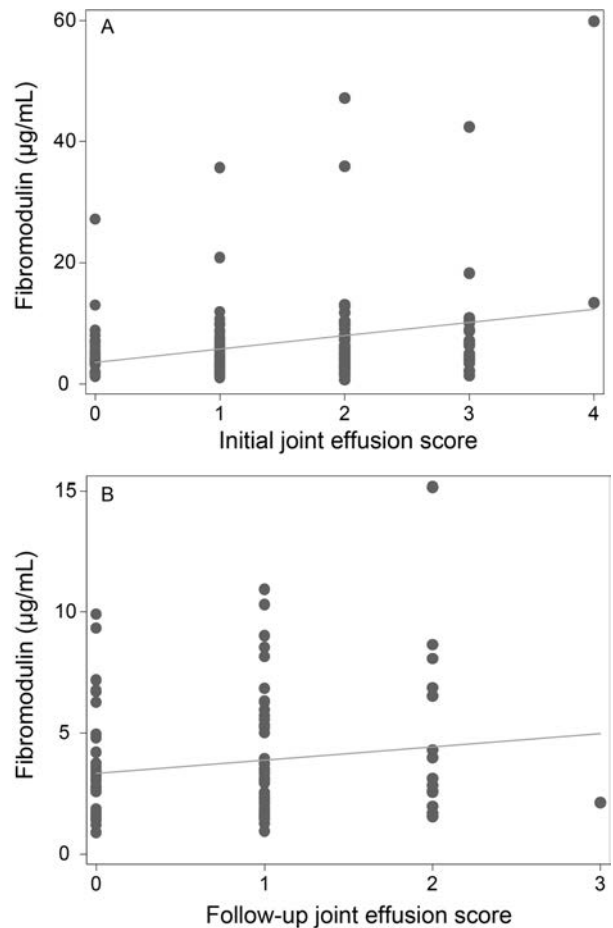


Figure 3—Scatterplots of joint effusion score (scored on a scale from 0 to 4) versus fibromodulin concentration in synovial fluid collected prior to surgery from 115 horses (163 joints) with OCD of the TCJ (A) and from 73 of the horses (105 joints) approximately 6 months after arthroscopic removal of osteochondral fragments. In each graph, the solid line represents the linear regression.

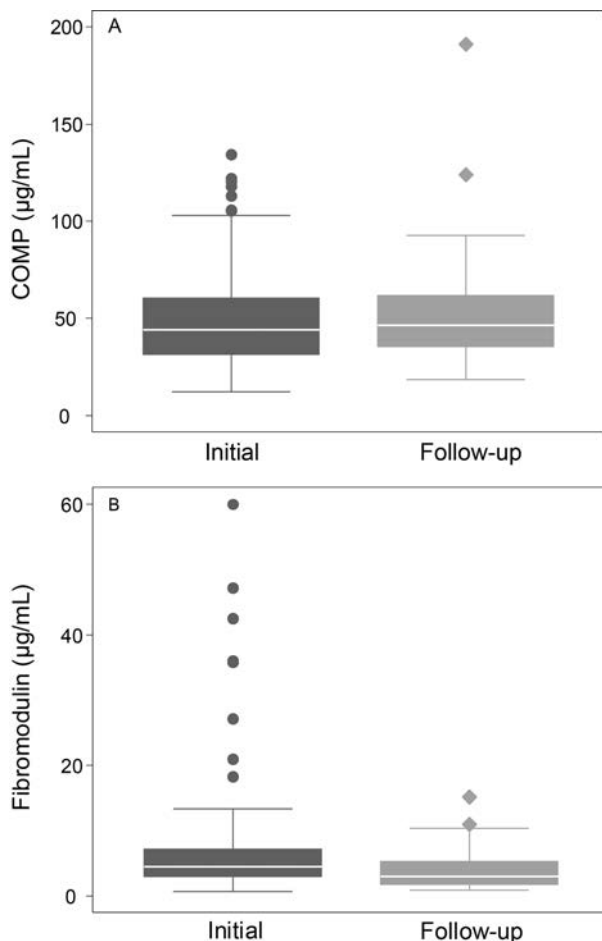


Figure 4—Box plots of COMP (A) and fibromodulin (B) concentrations in synovial fluid collected prior to surgery from 115 horses (163 joints) with OCD of the TCJ (Initial) and from 73 of the horses (105 joints) at the time of follow-up examination approximately 6 months after arthroscopic removal of osteochondral fragments (Follow-up). See Figure 1 for key.

vial fluid COMP ($P = 0.18$) or fibromodulin ($P = 0.52$) concentration. Similarly, synovial fluid total protein concentration for horses with OCD was not significantly correlated with synovial fluid COMP ($P = 0.24$) or fibromodulin ($P = 0.06$) concentration. Total protein concentration in the synovial fluid samples was only measured prior to surgery.

Histologic findings and COMP and fibromodulin concentrations

A statistically significant ($P < 0.01$) but likely clinically unimportant ($r^2 = 0.06$) correlation was found between synovial fluid fibromodulin concentration prior to surgery and histologic score for number of synoviocytes on the surface of the synovium ($n = 134$ joints; **Figure 5**). No other significant correlations between histologic findings and synovial fluid COMP or fibromodulin concentration were observed for horses with OCD or control horses.

Time to follow-up examination

For the 79 horses returned for follow-up examination after arthroscopic removal of osteochondral

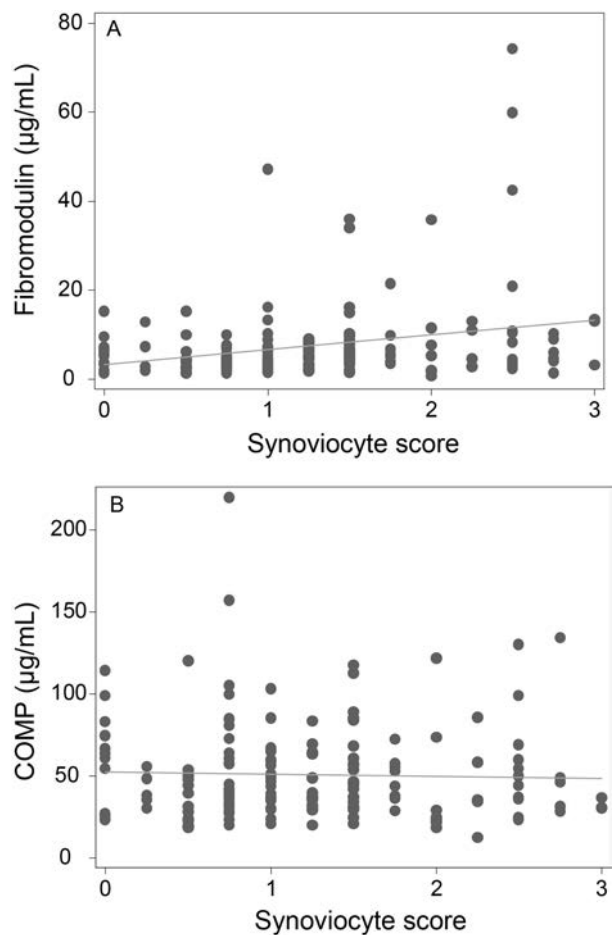


Figure 5—Scatterplots of scores for number of synoviocytes on the surface of the synovium (scored on a scale from 0 to 3) versus synovial fluid fibromodulin (A) and COMP (B) concentrations prior to surgery in 93 horses (134 joints) with OCD of the TCJ. In each graph, the solid line represents the linear regression.

fragments, mean \pm SD time to follow-up examination was 6.1 ± 3.8 months (median, 5 months; range, 1.25 to 20 months). No correlation was identified between time to follow-up examination and follow-up lameness score ($P = 0.83$) or between time to follow-up examination and results of a flexion test performed during the follow-up examination ($P = 0.81$). However, follow-up joint effusion scores were significantly ($P = 0.03$) decreased, compared with scores prior to surgery. No correlation was found between time to follow-up examination and follow-up COMP or fibromodulin concentration.

Discussion

Results of the present study suggested that fibromodulin could potentially be a biomarker for severity of joint inflammation in horses, in that synovial fluid fibromodulin concentration at the time of follow-up examination approximately 6 months after arthroscopic removal of osteochondral fragments from horses with naturally occurring OCD of the distal interme-

diate ridge of the tibia was significantly lower than the concentration prior to surgery and fibromodulin concentrations both prior to surgery and at the time of follow-up examination were significantly positively correlated with joint effusion scores. However, mean fibromodulin concentration prior to surgery was not significantly different from the mean concentration for control horses without TCJ abnormalities, and fibromodulin concentrations in horses with OCD were not significantly correlated with lameness scores or results of a flexion test. Also, although fibromodulin concentration prior to surgery was significantly correlated with synoviocyte score, the coefficient of determination was low, and fibromodulin concentration was not significantly correlated with inflammatory cell infiltration score. On the other hand, our findings suggested that COMP likely would not be a useful biomarker for joint inflammation in horses with OCD, in that synovial fluid COMP concentration in horses with OCD of the TCJ was not significantly different from concentration in control horses, did not decrease after arthroscopic removal of osteochondral fragments, and was not correlated with clinical (ie, joint effusion score, lameness score, or results of a flexion test) or histologic (ie, inflammatory cell infiltration score or synoviocyte score) signs of joint inflammation.

In contrast to our findings, COMP has previously been reported to be a potential biomarker of joint disease in both humans and horses. In a previous study,²⁴ for example, COMP concentration was significantly lower in synovial fluid from horses with moderately inflamed midcarpal joints than in synovial fluid from control horses, and 2 other studies^{3,23} have shown a decrease in COMP concentration in synovial fluid from horses with osteoarthritis. The disparity between our findings and results of these previous studies could reflect differences in the assays used to measure COMP concentration or differences in severity of the underlying disease process. In the present study, we used a polyclonal antiserum raised against equine COMP that detects both intact and fragmented COMP. Other assays^{23,25} have used monoclonal antibodies that only detect intact COMP and subsets of COMP fragments. In addition, horses with OCD in our study had relatively mild inflammation and mild clinical signs, whereas horses in the studies by Taylor et al,³ Misumi et al,²³ and Skiöldebrand et al²⁴ had moderate to severe joint disease. The mild inflammation in affected TCJs of horses with OCD in the present study may also explain why synovial fluid total protein concentration was not increased, compared with reference values for sound horses, and may help account for the lack of correlation between synovial fluid total protein concentration and synovial fluid COMP and fibromodulin concentrations.

In the present study, synovial fluid COMP and fibromodulin concentrations at the time of follow-up examination were found to be negatively correlated with age, meaning that concentrations decreased as age increased. This meant that the decrease in concen-

tration for both COMP and fibromodulin was greater for older horses. Similar findings have been reported in previous studies^{3,11,26} involving joint and tendon sheath fluids in horses. Consequently, age would appear to be a complicating factor for the use of COMP and fibromodulin as biomarkers of joint inflammation in horses, although age appears to have less of an effect on the concentration of these markers in mature horses.^{3,11}

Synovial fluid COMP concentrations following arthroscopic removal of osteochondral fragments were not significantly different from concentrations prior to surgery in the present study. It is possible that the preponderance of younger horses in our study population combined with the higher COMP concentrations in younger horses made it difficult for us to detect a significant difference. Nevertheless, the lack of correlations between COMP concentration and clinical and histologic signs of inflammation suggested that COMP would not be a useful marker for severity of joint inflammation associated with OCD. Cartilage oligomeric matrix protein could potentially be a marker for joint inflammation associated with diseases that predominate in mature or old horses, in that COMP concentration has been shown to decrease with osteoarthritis.^{3,11} However, we did not evaluate this possibility in the present study.

Synovial fluid fibromodulin concentration was positively correlated with joint effusion score in the present study, suggesting that increases in synovial fluid volume did not result in substantial dilution of this marker. Also, synovial fluid concentration of fibromodulin decreased significantly after arthroscopic removal of osteochondral fragments. A previous study²⁹ found that fibromodulin can activate the complement system, and we think it is possible that the reduced concentration of fibromodulin in the synovial fluid after surgery may, at least partially, have been responsible for the reduced signs of inflammation.

Because the synovium contains fibromodulin but only low concentrations of COMP, compared with concentrations in articular cartilage,¹¹ our findings suggested that OCD may have greater effects on the synovium than on the cartilage itself. However, more research is needed before any conclusions can be drawn.

Finally, the present study was, in large part, hypothesis generating, and more research is needed to determine whether the decrease in synovial fluid fibromodulin concentration after surgery was a result of a reduction in activation of components of inflammation or a consequence of reduced inflammation following surgery limiting fibromodulin release.

Acknowledgments

This manuscript represents a portion of a thesis submitted by Dr. Brink to the Norwegian School of Veterinary Science Department of Companion Animals as partial fulfillment of the requirements for a Doctor of Philosophy degree.

Supported by the research foundations of Foreningen Kustos, G. Forssell, Swedish Trot and Gallop Equine Clinics, A. B. Torsted, Vetfond,

H. P. Christensen, M. Forsgren, H. P. Olsen, R. Nortoft Thomsen, Kingdom DKs Horse Insurance, H. Nielsen, U. Yard, Agria Insurance, Vet Science Workers, Vet Science Advancement, B. Bang, and Intervet DK. Funding sources did not have any involvement in the study design, data analysis and interpretation, or writing and publication of the manuscript.

The authors thank Professor D. Heinegård for assistance with the ELISAs for synovial fluid COMP and fibromodulin concentrations and for manuscript discussion.

Footnotes

- a. Mepivacaine hydrochloride, AstraZeneca Sweden AB, Södertälje, Sweden.
- b. Histofix, Histolab Products AB, Göteborg, Sweden.
- c. Sterilin, Labssystem, Stockholm, Sweden.
- d. Maxisorp, Nunc, Copenhagen, Denmark.
- e. Dako, Glostrup, Denmark.
- f. Multiscan Multisort, Labsystems, Stockholm, Sweden.
- g. Stata, release 10, StataCorp LP, College Station, Tex.

References

1. Brink P, Dolvik NI, Tverdal A. Lameness and effusion of the tarsocrural joints after arthroscopy of osteochondritis dissecans in horses. *Vet Rec* 2009;165:709-712.
2. Brink P, Skydsgaard M, Teige J, et al. Association between clinical signs and histopathologic changes in the synovium of the tarsocrural joint of horses with osteochondritis dissecans of the tibia. *Am J Vet Res* 2010;71:47-54.
3. Taylor SE, Weaver MP, Pitsillides AA, et al. Cartilage oligomeric matrix protein and hyaluronan levels in synovial fluid from horses with osteoarthritis of the tarsometatarsal joint compared to a control population. *Equine Vet J* 2006;38:502-507.
4. Bertone AL, Palmer JL, Jones J. Synovial fluid cytokines and eicosanoids as markers of joint disease in horses. *Vet Surg* 2001;30:528-538.
5. Fuller CJ, Barr AR, Sharif M, et al. Cross-sectional comparison of synovial fluid biochemical markers in equine osteoarthritis and the correlation of these markers with articular cartilage damage. *Osteoarthritis Cartilage* 2001;9:49-55.
6. Saxne T, Heinegård D. Cartilage oligomeric matrix protein: a novel marker of cartilage turnover detectable in synovial fluid and blood. *Br J Rheumatol* 1992;31:583-591.
7. Heinegård D, Saxne T. Macromolecule markers in joint disease. *J Rheumatol Suppl* 1991;27:27-29.
8. Lorenzo P, Bayliss MT, Heinegård D. Altered patterns and synthesis of extracellular matrix macromolecules in early osteoarthritis. *Matrix Biol* 2004;23:381-391.
9. Oldberg A, Antonsson P, Lindblom K, et al. COMP (cartilage oligomeric matrix protein) is structurally related to the thrombospondins. *J Biol Chem* 1992;267:22346-22350.
10. Hedbom E, Antonsson P, Hjerpe A, et al. Cartilage matrix proteins. An acidic oligomeric protein (COMP) detected only in cartilage. *J Biol Chem* 1992;267:6132-6136.
11. Smith RKW, Zunino L, Webbon PM, et al. The distribution of cartilage oligomeric matrix protein (COMP) in tendon and its variation with tendon site, age and load. *Matrix Biol* 1997;16:255-271.
12. Murray RC, Smith RK, Henson FM, et al. The distribution of cartilage oligomeric matrix protein (COMP) in equine carpal articular cartilage and its variation with exercise and cartilage deterioration. *Vet J* 2001;162:121-128.
13. Skiöldebrand E, Heinegård D, Olofsson B, et al. Altered homeostasis of extracellular matrix proteins in joints of standardbred trotters during a long-term training programme. *J Vet Med A Physiol Pathol Clin Med* 2006;53:445-449.
14. Skiöldebrand E, Ekman S, Heinegård D, et al. Ultrastructural immunolocalization of cartilage oligomeric matrix protein (COMP) in the articular cartilage on the equine third carpal bone in trained and untrained horses. *Res Vet Sci* 2010;88:251-257.
15. Briggs MD, Hoffman SMG, King LM, et al. Pseudoachondroplasia and multiple epiphyseal dysplasia due to mutations in the cartilage oligomeric matrix protein gene. *Nat Genet* 1995;10:330-336.
16. Hecht JT, Nelson LD, Crowder E, et al. Mutations in exon 17B of cartilage oligomeric matrix protein (COMP) cause pseudoachondroplasia. *Nat Genet* 1995;10:325-329.
17. Rosenberg K, Olsson H, Morgelin M, et al. Cartilage oligomeric matrix protein shows high affinity zinc-dependent interaction with triple helical collagen. *J Biol Chem* 1998;273:20397-20403.
18. Holden P, Meadows RS, Chapman KL, et al. Cartilage oligomeric matrix protein interacts with type IX collagen and disruptions to these interactions identify a pathogenic mechanism in a bone dysplasia family. *J Biol Chem* 2001;276:6046-6055.
19. Di Cesare PE, Chen FS, Morgelin M, et al. Matrix-matrix interaction of cartilage oligomeric matrix protein and fibronectin. *Matrix Biol* 2002;21:461-470.
20. Xu K, Zhang Y, Ilalov K, et al. Cartilage oligomeric matrix protein associates with granulin-epithelin precursor (GEP) and potentiates GEP-stimulated chondrocyte proliferation. *J Biol Chem* 2007;282:11347-11355.
21. Koelling S, Clauditz TS, Kaste M, et al. Cartilage oligomeric matrix protein is involved in human limb development and in the pathogenesis of osteoarthritis. *Arthritis Res Ther* 2006;8:R56.
22. Lohmander LS, Saxne T, Heinegård DK. Release of cartilage oligomeric matrix protein (COMP) into joint fluid after knee injury and in osteoarthritis. *Ann Rheum Dis* 1994;53:8-13.
23. Misumi K, Vilim V, Clegg CCM, et al. Measurement of cartilage oligomeric matrix protein (COMP) in normal and diseased equine synovial fluids. *Osteoarthritis Cartilage* 2001;9:119-127.
24. Skiöldebrand E, Lorenzo P, Zunino L, et al. Concentration of collagen, aggrecan and cartilage oligomeric matrix protein (COMP) in synovial fluid from equine middle carpal joints. *Equine Vet J* 2001;33:394-402.
25. Arai K, Misumi K, Carter SD, et al. Analysis of cartilage oligomeric matrix protein (COMP) degradation and synthesis in equine joint disease. *Equine Vet J* 2005;37:31-36.
26. Skiöldebrand E, Heinegård D, Eloranta ML, et al. Enhanced concentration of COMP (cartilage oligomeric matrix protein) in osteochondral fractures from racing Thoroughbreds. *J Orthop Res* 2005;23:156-163.
27. Viitanen M, Bird J, Maisi R, et al. Differences in the concentration of various synovial fluid constituents between the distal interphalangeal joint, the metacarpophalangeal joint and the navicular bursa in normal horses. *Res Vet Sci* 2000;69:63-67.
28. Heinegård D, Larsson T, Sommarin Y, et al. Two novel matrix proteins isolated from articular cartilage show wide distributions among connective tissues. *J Biol Chem* 1986;261:13866-13872.
29. Sjöberg A, Onnerfjord P, Morgelin M, et al. The extracellular matrix and inflammation. Fibromodulin activates the classical pathway of complement by directly binding C1q. *J Biol Chem* 2005;280:32301-32308.
30. Heathfield TF, Onnerfjord P, Dahlberg L, et al. Cleavage of fibromodulin in cartilage explants involves removal of the N-terminal tyrosine sulfate-rich region by proteolysis at a site that is sensitive to matrix metalloproteinase-13. *J Biol Chem* 2004;279:6286-6295.
31. Lauder RM, Huckerby TN, Niedzczynski IA. The structure of the keratan sulphate chains attached to fibromodulin from human articular cartilage. *Glycoconj J* 1997;14:651-660.
32. Heinegård D, Oldberg A. Structure and biology of cartilage and bone matrix non-collagenous macromolecules. *FASEB J* 1989;3:2042-2051.
33. Hedlund H, Mengarelli-Widholm S, Heinegård D, et al. Fibromodulin distribution and association with collagen. *Matrix Biol* 1994;14:227-232.
34. Coleman P, Kavanagh E, Mason RM, et al. The proteoglycans and glycosaminoglycan chains of rabbit synovium. *Histochem J* 1998;30:519-524.

35. Ekman S, Heinegard D, Johnell O, et al. Immunohistochemical localization of proteoglycans and non-collagenous matrix proteins in normal and osteochondrotic porcine articular-epiphyseal cartilage complex. *Matrix* 1990;10:402-411.
36. Jaovisidha K, Etim A, Yamakawa K, et al. The serine protease inhibitor trappin-2 is present in cartilage and synovial fluid in osteoarthritis. *J Rheumatol* 2006;33:318-325.
37. Ross MW. Movement. In: Ross MW, Dyson SJ, eds. *Diagnosis and management of lameness in the horse*. Philadelphia: Saunders, 2002;66-67.
38. Bergin BJ, Pierce SW, Bramlage LR, et al. Oral hyaluronan gel reduces post operative tarsocrural effusion in the yearling Thoroughbred. *Equine Vet J* 2006;38:375-378.
39. Smith MR, Wright IM, Minshall GJ, et al. An increased cartilage oligomeric matrix protein concentration in equine digital flexor tendon sheath synovial fluid predicts intrathecal tendon damage. *Vet Surg* 2011;40:54-58.