

Effects of experimental mechanical manipulations on local inflammation in the jejunum of horses

Charlotte C. S. Hopster-Iversen, DrMedVet; Klaus Hopster, DrMedVet; Carsten Staszky, DrMedVet; Karl Rohn, DrMedVet; David E. Freeman, MVB, PhD; Anna K. Rötting, DrMedVet, PhD

Objective—To determine characteristics of the inflammatory reaction in the jejunum of horses in response to various mechanical manipulations.

Animals—12 adult warmblood horses without gastrointestinal tract disorders.

Procedures—The proximal aspect of the jejunum in each horse was divided into 5 segments, and the following manipulations were performed: manual emptying, placement of Doyen forceps, enterotomy alone, enterotomy with mucosal abrasion, and serosal abrasion. Jejunum samples were collected before (control), immediately after, and 30 minutes after the end of manipulations and histologically evaluated to determine distribution of neutrophils and eosinophils.

Results—Macroscopically, all manipulations resulted in jejunal hemorrhage and edema. Compared with control samples, neutrophil numbers were significantly higher after manipulations in the serosa (after all manipulation types), circular muscle layer (after manual emptying), submucosa (after placement of Doyen forceps), and mucosa (after all manipulations except enterotomy alone). Eosinophil numbers were significantly higher in the submucosa after mechanical abrasion of the serosa and manual emptying versus control samples.

Conclusions and Clinical Relevance—Results indicated mechanical manipulation of the jejunum resulted in local inflammatory reactions characterized predominantly by infiltration of neutrophils. This could contribute to the development of postoperative ileus or adhesions in horses without macroscopically detectable injury of the jejunum during surgery. (*Am J Vet Res* 2014;75:385–391)

The development of POI is a major complication in horses after colic surgery.¹ A factor that may lead to the development of POI is a local inflammatory reaction in the gastrointestinal tract. Mechanical manipulation can induce various degrees of intestinal inflammation in laboratory animals, pigs, horses, and humans.^{2–7}

Received August 7, 2013.

Accepted October 31, 2013.

From the Equine Clinic (Hopster-Iversen, Hopster, Rötting) and the Institute of Biometry, Epidemiology, and Information Processing (Rohn), University of Veterinary Medicine Hannover, 30559 Hannover, Germany; the Institute of Veterinary Anatomy, Histology and Embryology, Justus-Liebig University, 35390 Giessen, Germany (Staszky); and the Island Whirl Equine Colic Research Laboratory, Department of Large Animal Clinical Sciences, College of Veterinary Medicine, University of Florida, Gainesville, FL 32611 (Freeman).

The study was performed at the Equine Clinic, University of Veterinary Medicine Hannover, 30559 Hannover, Niedersachsen, Germany.

Presented as an oral presentation at the 5th Annual Congress of the European College of Equine Internal Medicine, Edinburgh, February 2012.

This manuscript represents a portion of a thesis submitted by Dr. Hopster-Iversen to the University of Veterinary Medicine Hannover as partial fulfillment of the requirements for a Doctor of Philosophy Degree.

The authors thank Gudrun Wirth for technical assistance.

Address correspondence to Dr. Hopster-Iversen (Charlotte.Iversen@gmx.de).

ABBREVIATION

POI Postoperative Ileus

Local effects of mechanical manipulation of intestines include an inflammatory response in the muscularis externa of the small intestine after surgical manipulation in rodents.² This results in progressive neutrophil infiltration that peaks on postoperative day 1 and a decrease in circular muscle contractility in vitro.² Mechanical manipulations can also affect intestine that has not been directly manipulated. Surgical manipulation of jejunum in rodents results in panenteritis.³ Such animals have a decrease in jejunal contractions and gastric emptying time and an increase in gastrointestinal transit time; in addition, colonic circular muscle contractility is decreased in vitro.³ The effects of laparotomy and traditional surgical techniques in pigs have been compared; performance of gastrectomy with intestinal handling results in more severe inflammation than laparoscopically assisted gastrectomy without intestinal manipulation.⁴ In human patients, traditional gynecologic surgical procedures cause a higher amount of mast cell activation in peritoneal fluid in contrast to minimally invasive surgical procedures.⁵

In horses, inflammation rapidly develops in colonic mucosa and serosa after direct mechanical manipula-

tion or jejunal ischemia and reperfusion.⁸ Neutrophil and eosinophil granulocytes are involved in the inflammatory response for both of those experimental conditions.⁸ Neutrophil granulocytes are inflammatory cells located predominantly in the blood circulation that are recruited to tissues in response to various stimuli. Neutrophil granulocytes are the predominant inflammatory cell type associated with intestinal inflammation after ischemia and reperfusion.^{9–14} In horses, neutrophil infiltration develops after ischemia and reperfusion injury in the small intestine¹⁵ and large colon¹⁶ and after distension of the small colon.¹⁷ In another study,¹⁵ neutrophil infiltration of jejunal serosa and, less severely, of circular muscle developed after mechanical emptying of the jejunum in preparation for experimental induction of ischemia and reperfusion in horses.

Eosinophil granulocytes are part of the resident cell population of equine intestinal submucosa and mucosa.¹⁸ Results of other studies indicate mucosal eosinophil granulocytes in horses respond to various stimuli such as parasite infection^{19,20} and mucosal injury *in vitro* after mechanical manipulation of the colon.²¹ Eosinophils in the colon also respond after experimental induction of jejunal ischemia and reperfusion without prior manipulation of the colon.⁸ Eosinophil granulocytes are capable of initiating and maintaining a local inflammatory reaction.²² Therefore, characteristics of eosinophil and neutrophil granulocyte responses are of interest for improving understanding of the pathogenesis and clinical consequences of intestinal inflammation in horses.

The objective of the study reported here was to determine characteristics of the local jejunal inflammatory reaction in horses after performance of mechanical manipulations, similar to those used during colic surgery. In particular, the objective was to determine the distribution and numbers of neutrophil and eosinophil granulocytes in jejunum after such manipulations. We hypothesized that mechanical manipulations would lead to a measurable local inflammatory reaction in each intestinal wall layer.

Materials and Methods

Horses—This study was approved by the Ethical Commission of the Veterinary University of Hannover, Germany. Twelve adult horses of various breeds with a mean age of 12.4 years (range, 3 to 25 years) and mean weight of 531.7 kg (range, 470 to 565 kg) without signs of gastrointestinal tract disorders were included. Two weeks before the start of the study, the horses received moxidectin^a in accordance with the manufacturer's recommendations and fecal samples were evaluated to detect intestinal parasites by use of a fecal flotation test; results were negative (no parasite eggs were detected in fecal samples) for all horses. Horses were kept in stalls with paddock turnout and allowed unlimited access to hay and water for 2 weeks prior to the start of the study.

Study design—Horses received xylazine^b (0.8 to 1.1 mg/kg, IV), and anesthesia was induced with diazepam^c (0.05 mg/kg, IV) and ketamine^d (2.2 mg/kg, IV). Following anesthetic induction and tracheal intubation, horses were positioned in dorsal recumbency.

Anesthesia was maintained with isoflurane^e in 100% oxygen and a continuous rate infusion of xylazine^b (0.7 mg/kg/h). Mean arterial blood pressure, heart rate, respiratory rate, respiratory pressure, fraction of inspired oxygen, and expiratory isoflurane concentration were monitored continuously,^f and arterial blood gas values were measured every 20 minutes. Dobutamine,^g lactated Ringer's solution,^h and hydroxyethylstarchⁱ were administered IV to effect to maintain mean arterial blood pressure > 60 mm Hg. Horses did not receive lidocaine.

Surgical procedure—After routine aseptic preparation, a ventral midline laparotomy was performed and the proximal aspect of the jejunum approximately 1 m aboral from the duodenocolic ligament was exteriorized and divided into 5 adjoining 30-cm-long segments with umbilical tape without compromising the vascular supply. One of 5 manipulation types was performed for each of the 5 jejunal segments. For group 1 (manual emptying) manipulations, repeated manual decompression of intestine was performed (approx 1 stroke/s) for 10 minutes to simulate such manipulations typically performed during colic surgery (ie, running of the bowel). This manipulation type was performed with the most distal jejunal segment in each horse; the distal aspect of this segment was not obstructed with umbilical tape. For group 2 (Doyen forceps) manipulations, Doyen forceps was applied to the most proximal jejunal segments in each horse. These segments were placed in the abdomen for 30 minutes prior to jejunum sample collection.

The other jejunal segments underwent 1 of 3 manipulation types (determined by use of a randomization procedure). For group 3 (enterotomy) manipulations, an enterotomy was performed at the antimesenteric border without further manipulation. For group 4 (mucosal abrasion) manipulations, enterotomies were performed at the antimesenteric border followed by mechanical abrasion of the mucosa with moist sponges for 10 minutes. For group 5 (serosal abrasion) manipulations, mechanical abrasion of the serosa was performed with moist sponges for 10 minutes.

Full-thickness jejunal wall samples (2 × 2 cm) were collected at 3 times from the antimesenteric aspect of jejunal segments in each horse. Collection times included a control time (before the start of intestinal manipulations) and 0 (immediately after the end of mucosal [group 4] or serosal abrasion [group 5], manual emptying [group 1], or removal of Doyen forceps [group 2] or 10 minutes after enterotomy [group 3]) and 30 minutes after manipulations. After collection of all jejunum samples, horses were euthanatized with an overdose of sodium pentobarbital^j while they were anesthetized. The same investigator (AKR) performed all surgeries and mechanical manipulations of jejunal segments.

Histologic evaluation—Jejunum samples were fixed in neutral-buffered 10% formalin and Bouin's solution (formaldehyde, picric acid, and acetic acid), embedded in paraffin, and sectioned (thickness, 5 μm). All histologic examinations were performed by the same investigator (CCSHI) who was unaware of the manipulation groups for each sample of jejunum. Slides were

stained with Luna's eosinophil stain for determination of accumulation and distribution of eosinophils. For performance of Luna's eosinophil stain, Bouin's solution-fixed slides were desiccated in xylene, stained with Biebrich scarlet-hematoxylin, differentiated in 1% acid alcohol, and stained with lithium carbonate. With this stain, eosinophil granules and Charcot-Leyden crystals stain red, erythrocytes stain orange, and all nuclear elements stain blue.²³

Neutrophil granulocytes were identified by use of immunohistochemical staining of calprotectin.^{15,16} Although calprotectin is also expressed in activated macrophages, the correlation between the number of cells with calprotectin staining and the number of neutrophils is strong in tissue samples obtained from horses with experimentally induced ischemia and reperfusion.¹⁶ Formalin-fixed jejunum sample sections were dewaxed and treated with blocking agents^k to prevent nonspecific interactions between proteins and actions of endogenous peroxidases. Sections were incubated (8°C) with primary antibody against calprotectin^l (dilution, 1:400). Then, sections were incubated (25°C) with biotinylated immunoglobulin^m for 20 minutes. A commercially available immunohistochemical staining kitⁿ was used for detection of antigen-antibody complexes. Sections were incubated (25°C) with horseradish peroxidase-labeled streptavidin for 20 minutes. The antibody-enzyme complexes were detected with a chromogenⁿ until adequate color development was observed. Slides were washed in water to stop the re-

action, counterstained with toluidine blue, and covered with mounting medium and then coverslips were applied.

Images of sections of jejunum were obtained by means of light microscopy, and image analysis software^o was used for histomorphometric analysis. The histomorphometric measurements were performed as previously described.¹⁸ The mucosa was divided into 5 zones as follows: the mean distance from the muscularis mucosae to the base of the villi was divided into 2 successive zones (M1 and M2); the mean distance from the base of the villi to the tip of the villi was divided into 2 successive zones (M3 and M4); and the luminal surface of the epithelial cells was zone M5. Absolute numbers of eosinophils and neutrophils were counted in 3 fields for each zone, and the mean number of eosinophils or neutrophils in each zone was calculated. These mean values were used to calculate the percentage of eosinophils or neutrophils in each of the 5 zones relative to the total eosinophil or neutrophil count in all zones for each horse as a measure of cell distribution in the mucosa (Figure 1). The absolute number of eosinophils and neutrophils per square millimeter of mucosa (from the muscularis mucosae to the base of the villi [zones M1 and M2]) was calculated as a measure of eosinophil or neutrophil accumulation. The length of mucosal surface epithelium was measured, and the percentage of denuded epithelium was calculated.

In addition, the other histologic layers of the jejunum wall (serosa, longitudinal muscle layer, intermuscular layer, circular muscle layer, and submucosa) were evaluated to detect neutrophil and eosinophil accumulation. For this purpose, a rectangular field (250 × 390 μm) was superimposed over 3 randomly selected areas of each wall layer, the absolute number of eosinophils and neutrophils were counted, and the mean number of cells per square millimeter of each tissue layer was calculated. In the circular and longitudinal muscle layers, these rectangles were positioned adjoining the intermuscular layer; a 100× magnification was used for microscopic examination. For the serosa and the intermuscular layer, a magnification of 200× was used. The submucosa was further divided into 3 zones (SM1, SM2, and SM3), with zone SM1 next to the lamina muscularis mucosae and zone SM3 adjacent to the circular

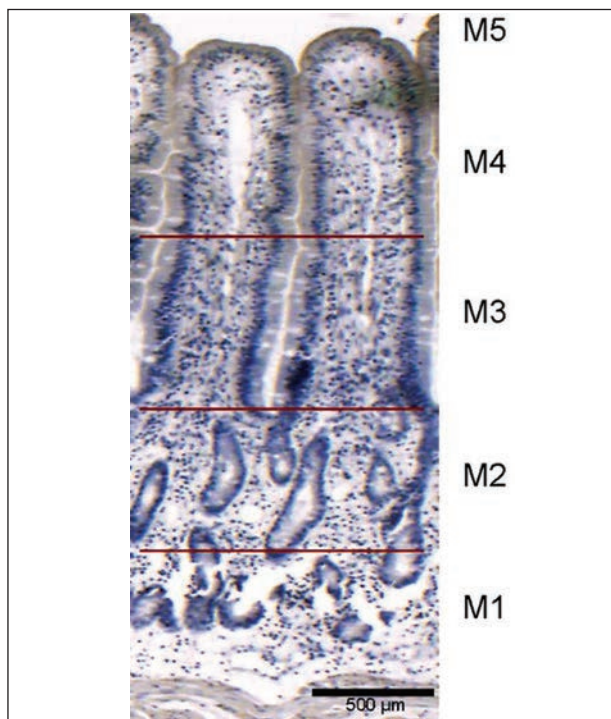


Figure 1—Photomicrograph of a section of the proximal aspect of the jejunum of a horse indicating the division of mucosa into segments (M1 through M5) for purposes of histologic evaluation. The mean distance from the muscularis mucosae to the base of the villi was calculated and divided in 2 equal segments (M1 and M2). The mean length of the villi was calculated and divided into 2 equal segments (M3 and M4). Segment M5 was the luminal side of the mucosa. Luna's eosinophil stain; bar = 500 μm.




Figure 2—Photomicrograph of a section of the proximal aspect of the jejunum of a horse indicating 3 zones of submucosa (SM1 through SM3; size of each zone, 250 × 390 μm) for purposes of histologic evaluation. Zone SM1 included submucosa adjacent to the muscularis mucosae, zone SM3 included submucosa bordering the circular muscle layer, and zone SM2 was located midway between SM1 and SM3. Luna's eosinophil stain; bar = 500 μm.

muscular layer (Figure 2); a magnification of 200X was used for microscopic evaluation.

Statistical analysis—Goodness of fit for a normal distribution of model residuals of all variables was rejected by means of visual assessment of normal probability plots and the Kolmogorov-Smirnov test (ie, data did not have normal or log-normal distribution). Therefore, nonparametric methods were used for

analysis of data, and median, minimum, and maximum values were determined for all variables. Independent samples were compared by use of the Wilcoxon 2-sample test. For repeated measurements, pairwise comparisons were performed with the signed rank test. Values of $P < 0.05$ were considered significant. Analyses were performed with statistical software.^P

Results

All tested mechanical manipulations resulted in macroscopically detectable marked edema and hemorrhage of intestinal walls (Figure 3). For group 1 jejunal segments, manual emptying manipulations resulted in significantly higher neutrophil counts in the mucosa of jejunum samples obtained 30 minutes after manipulations versus those in the mucosa of control samples ($P = 0.042$), in the circular muscle layer of jejunum samples obtained 30 minutes after manipulations versus neutrophil counts in that layer of control samples ($P = 0.031$), and in the serosa of jejunum samples obtained immediately after manipulations ($P = 0.040$) and 30 minutes after manipulations ($P = 0.002$) versus neutrophil counts in that layer of control samples (Table 1). For group 1 jejunum samples, the eosinophil count in zone SM2 of submucosa in samples obtained 30 minutes after manipulations was significantly ($P = 0.031$) higher than it was in that zone of control samples.

For group 2 jejunal segments, application of Doyen forceps resulted in significantly higher neutrophil counts in the mucosa immediately ($P = 0.042$) and 30 minutes ($P = 0.007$) after manipulation versus neutrophil counts in that layer of control samples (Table 1). In addition, submucosa (zones SM1 and SM2) and serosa had significantly higher neutrophil counts 30 minutes after manipulation versus neutrophil counts in those layers of control samples (SM1, $P = 0.016$; SM2, $P = 0.016$; serosa, $P = 0.020$). Results of histomorphometric analysis indicated a significantly higher percentage of denuded villi immediately ($P = 0.045$) and 30 minutes ($P = 0.002$) after Doyen forceps manipulation, compared with the percentage in control samples.

For group 3 jejunal segments, enterotomy resulted in significantly higher neutrophil counts in serosa 30 minutes after manipulation, compared with counts in

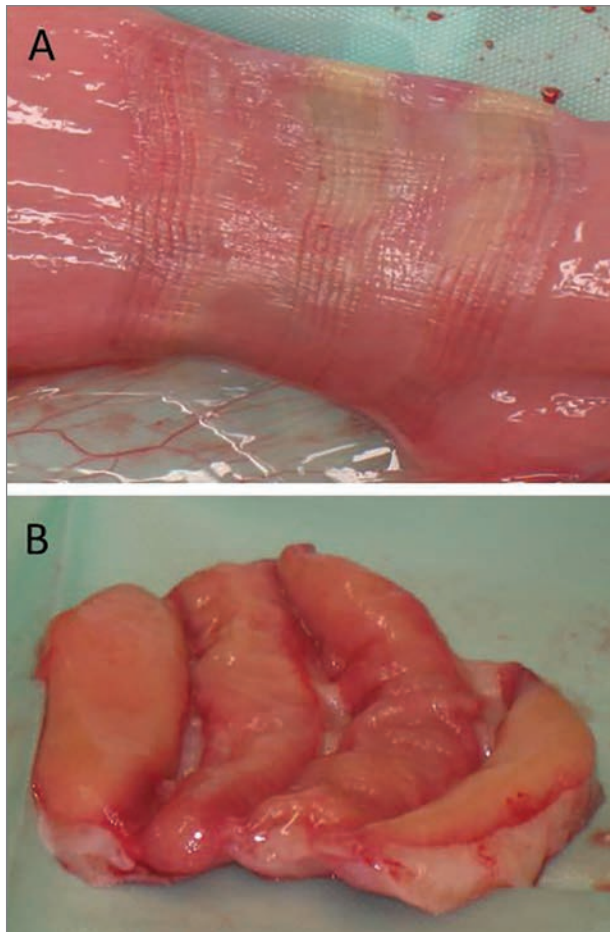


Figure 3—Representative photographic images of the serosal (A) and mucosal (B) surfaces of a segment of jejunum immediately after removal of Doyen forceps.

Table 1—Neutrophil counts in histologic layers of jejunal wall samples obtained from 12 horses before (control) and 0 and 30 minutes after various experimental manipulations.

Histologic layer	Control	Manual emptying		Doyen forceps		Enterotomy		Enterotomy and mucosal abrasion		Serosal abrasion	
		t0	t30	t0	t30	t0	t30	t0	t30	t0	t30
Mucosa	1 (0–13.54)	7.55 (0–15.29)	8.23* (0–53.25)	6.33* (0–30.84)	14.24* (0–103.67)	0.6 (0–19.8)	2.13 (0–38)	4.45 (0–15.57)	19.63**† (2.88–29.84)	4.36 (0–38.02)	8.46* (0–20.31)
Submucosa											
SM1	0 (0–15.38)	3.41 (0–13.68)	1.71 (0–10.26)	3.42 (0–13.68)	6.84* (0–211.97)	0 (0–17.09)	0 (0–6.84)	0 (0–6.84)	5.13 (0–208.55)	0 (0–13.68)	0 (0–17.09)
SM2	0 (0–6.84)	1.71 (0–10.26)	3.41 (0–23.33)	0 (0–71.79)	5.13* (0–109.4)	1.71 (0–205.13)	3.42 (0–71.79)	1.71 (0–23.33)	0 (0–82.05)	0 (0–3.42)	0 (0–30.77)
SM3	0 (0–3.42)	0 (0–10.26)	0 (0–17.09)	0 (0–6.84)	0 (0–10.26)	0 (0–10.26)	0 (0–13.68)	0 (0–3.42)	0 (0–3.33)	0 (0–3.42)	0 (0–6.84)
Circular muscle	0 (0)	0 (0–6.84)	1.71* (0–17.09)	0 (0–6.84)	0 (0–3.41)	0 (0)	0 (0–3.42)	0 (0–3.42)	0 (0–34.19)	0 (0–17.09)	0 (0–3.41)
Longitudinal muscle	0 (0)	0 (0–3.42)	0 (0)	0 (0)	0 (0–2)	0 (0)	0 (0–5.13)	0 (0–5.13)	0 (0–23.33)	0 (0–3.41)	0 (0–1)
Serosa	0 (0–5.13)	3.41* (0–119.66)	8.55* (0–174.36)	0 (0–34.19)	5.13* (0–82.05)	0 (0–20.51)	28.21**† (0–92.31)	0 (0–3.42)	41.03**† (13.68–164.1)	0 (0–10.26)	8.55**† (0–61.54)

Values are expressed as median (range) number of neutrophils per square millimeter. Values were determined by use of mean values for 3 microscopic fields of each histologic layer for each horse.

*Within a histologic layer, value is significantly ($P < 0.05$) different from value for control samples. †Within a histologic layer and manipulation group, value is significantly ($P < 0.05$) different between jejunum samples obtained immediately after manipulation and those obtained 30 minutes later.

SM = Histologic submucosa zone. t0 = Immediately after the end of manipulations. t30 = 30 minutes after the end of manipulations.

that layer of control samples ($P = 0.006$) and samples obtained immediately after end of manipulation ($P = 0.004$; Table 1). In addition, enterotomy resulted in significantly ($P = 0.004$) higher neutrophil counts in serosa 30 minutes after manipulation, compared with counts in that layer of samples obtained immediately after manipulation.

For group 4 jejunal segments, enterotomy and mucosal abrasion resulted in significantly higher neutrophil counts in the mucosa 30 minutes after manipulation, compared with neutrophil counts in that layer of control samples ($P = 0.001$) and samples obtained immediately after manipulation ($P < 0.001$; Table 1). Enterotomy and mucosal abrasion resulted in significantly higher neutrophil counts in the submucosa (section SM1) 30 minutes after manipulation, compared with neutrophil counts in control samples ($P = 0.031$) and samples obtained immediately after manipulation ($P = 0.043$). Enterotomy and mucosal abrasion resulted in significantly higher neutrophil counts in serosa 30 minutes after manipulation, compared with neutrophil counts in control samples ($P = 0.001$) and samples obtained immediately after manipulation ($P = 0.002$). The percentage of denuded villi for group 4 jejunal samples was significantly higher immediately ($P < 0.001$) and 30 minutes ($P = 0.004$) after manipulation than it was in control samples.

For group 5 jejunal segments, serosal abrasion resulted in significantly ($P = 0.010$) higher neutrophil counts in mucosa 30 minutes after manipulation, compared with neutrophil counts in control samples (Table 1). In addition, group 5 jejunum samples had significantly higher neutrophil counts in serosa 30 minutes after manipulation, compared with counts in control samples ($P = 0.004$) and samples obtained immediately after manipulation ($P = 0.041$). Eosinophil counts in the submucosa were significantly higher in jejunum samples obtained immediately ($P = 0.029$ for zone SM1) and 30 minutes ($P = 0.039$ for zone SM2) after manipulation versus eosinophil counts in those zones of control samples.

Discussion

In the present study, all evaluated mechanical manipulations of the jejunum induced a local inflammatory response. The manipulations performed were severe, but in the authors' opinion, similar manipulations could be performed during colic surgery, especially when performed by a surgeon with a small amount of experience. Also, distended loops of small intestine may have a stronger inflammatory reaction to less severe stimuli versus physiologically normal intestine. The weakest inflammatory response detected in this study was for jejunal segments in which enterotomy alone was performed and the strongest response was detected in those in Doyen forceps and mucosal abrasion manipulation groups. The neutrophilic response seemed to be more pronounced than the eosinophilic response in jejunal segments. Infiltration with neutrophil granulocytes was detected in mucosa, submucosa, circular muscle, and serosa.

In the present study, the proximal aspect of the jejunum was evaluated, although many obstructive

problems in clinically affected horses involve the distal aspect of the jejunum. However, during laparotomy of horses, mechanical manipulations are performed for all aspects of the jejunum and motility disorders that develop after surgery often affect proximal aspects of the jejunum. Also, on the basis of results of a study² on rats in which the effects of mechanical manipulations on local inflammation in jejunum were determined, we did not expect a difference in the inflammatory reaction between proximal and distal aspects of the jejunum in horses.

The effects of mechanical manipulations on the local inflammatory reaction in jejunum of horses in this study were similar to those detected in other studies of laboratory animals. In 1 study,³ the effects of manipulation of the jejunum in rodents was determined. Results of that study indicated jejunal manipulation caused decreased jejunal contractions, gastric emptying and gastrointestinal transit times, and colonic circular muscle contractility in vitro; in addition, tumor necrosis factor- α , cyclooxygenase-2, and inducible nitric oxide synthase expression were significantly upregulated in manipulated jejunum, and neutrophil granulocytes were recruited into the muscularis externa of unmanipulated colon and stomach. Results of another study² indicate an inflammatory response develops in muscular layers of the small intestine of rats after surgical manipulation, with a progressive increase in neutrophil infiltration that peaks 1 day after surgery. In the present study, neutrophil infiltration of the circular muscle layer was detected after manual emptying of jejunum. Manual emptying (ie, running of the bowel) is typically performed during colic surgery for horses with small intestinal distension. Small intestinal lesions are typically associated with small intestinal distension, and horses with small intestinal lesions are predisposed to the development of POI.²⁴ Therefore, neutrophil infiltration of the circular muscle layer of small intestine may contribute to the development of POI.

Results of another study²⁵ indicate horses with strangulating small intestinal lesions have increased numbers of neutrophil granulocytes in the serosa of jejunal margins at the oral aspect of a resection and in the middle aspect of resected jejunal segments. Results of another study⁴ indicate horses that undergo small intestinal resection and subsequently develop POI have neutrophil infiltration of serosa and nonsignificantly increased neutrophil numbers in circular muscle of jejunal margins at the proximal aspects of resections, compared with findings for horses that do not develop POI after small intestinal resection. Experimentally induced ischemia and reperfusion injury of jejunum in horses results in infiltration of neutrophils that is more pronounced in the longitudinal muscle layer than it is in the circular muscle layer.¹ To the authors' knowledge, no information has been published regarding the clinical importance of neutrophil infiltration of only 1 or both layers of the muscularis externa in equine jejunum. Interestingly, different types of injury seem to have different effects on the 2 layers of the muscularis externa in the jejunum of horses, and it remains unclear whether neutrophil infiltration of the longitudinal muscle layer or the circular muscle layer in jejunum

may be more likely to predispose horses to the development of gastrointestinal tract motility disorders.

Local inflammation, the expression of kinetically active mediators, and a subsequent decrease in motility are possible etiologies for the development of POI.^{26–29} Other factors that may be involved in the development of POI include neuroimmune reflexes with an increase in the strength of the inhibitory sympathetic neural reflex³⁰ and the effects of anesthetics.^{31,32} Other investigators¹⁵ found higher numbers of neutrophils in small intestinal samples obtained 18 hours after surgery versus numbers of neutrophils in samples obtained immediately after surgery and suggested that finding indicates an inflammatory cause rather than a neurogenic cause for POI in horses.

Another potential consequence of neutrophil infiltration of serosa, such as that detected in jejunum samples after manipulations in the present study, is adhesion formation. Investigators of another study³³ compared the rate of adhesion formation after bowel resection by means of laparotomy versus that after bowel resection by means of laparoscopy in dogs; results indicated a significantly higher rate of adhesion formation after laparotomy, possibly because of the greater amount of mechanical manipulation during that procedure. Other authors³⁴ reported an adhesion prevalence of 32.3% in horses that underwent repeated laparotomy; results indicated no association between the site of the initial lesion or resection during the first surgery and the subsequent location of adhesion formation. These findings suggest that surgical trauma is a more important factor than the type and location of initial intestinal lesions for adhesion formation after surgery. Therefore, mechanical manipulation of bowel during surgery (such as repeatedly handling bowel) should be minimized to avoid unnecessary surgical trauma.

The use of Doyen forceps in the present study resulted in a macroscopically identifiable injury of the jejunal serosa and mucosa and a significant increase in neutrophil counts in the mucosa, submucosa, and serosa. Doyen forceps are sometimes used during colic surgery for occlusion of the ends of viable jejunum during resection and anastomosis. The local inflammatory reaction detected in the present study after removal of Doyen forceps was severe, and use of other methods of bowel occlusion during surgery may be preferable. In the present study, we did not evaluate long-term development of lesions caused by mechanical manipulation because horses were euthanized immediately after the jejunum samples were collected. However, in the author's experiences, intestinal lesions caused by application of Doyen forceps can be macroscopically identified several days after the initial surgery. In another study,³⁵ marks caused by application of Doyen forceps were visible 18 hours after the end of surgery and segments previously subjected to ischemia were identified by the marks of the Doyen forceps.

The eosinophilic response detected in jejunum of horses in the present study consisted of infiltration of submucosa after manual emptying of the bowel or serosal abrasion. A significant change in mucosal infiltration of eosinophils was not detected and, in contrast to results of other studies,^{8,21} no change in mucosal eo-

sinophil distribution was observed. However, the total number of eosinophil granulocytes in jejunal mucosa was very low, as is expected in the proximal aspect of the jejunum.¹⁸ Such low numbers of eosinophils might account for our inability to detect a significant eosinophilic response in the mucosa with the methods used in this study.

Results of this study indicated a rapid inflammatory response involving predominantly neutrophil granulocytes after mechanical manipulations of jejunum in horses. This response could contribute to postoperative complications in horses with colic and may explain why factors resulting in increased intestinal handling are associated with an increase in postoperative morbidity. These findings suggested that manipulation of bowel during surgery should be minimized. Running of the bowel should be performed as briefly and gently as possible. On the basis of results of this study, the use of Doyen forceps during jejunal anastomosis cannot be recommended, and if such instruments are used, the forceps should be closed with the least amount of force that allows bowel occlusion. However, data regarding the intestinal inflammatory response to other methods of temporary bowel occlusion (eg, Penrose drains) have not been determined, to the authors' knowledge. The results of this study should not be used to make decisions regarding the use of lubricants (ie, carboxymethylcellulose) during colic surgery because the study design did not allow differentiation between the effects of friction and effects of pressure on the jejunum during manual emptying.

- a. Equest Vétquinol GmbH, Ravensburg, Germany.
- b. Xylapan (Xylazine), CP-Pharma Handelsgesellschaft mbH, Burgdorf, Germany.
- c. Diazepam AbZ, AbZ Pharma GmbH, Blaubeuren, Germany.
- d. Narketan, Vétquinol GmbH, Ravensburg, Germany.
- e. Isofluran CP, CP-Pharma Handelsgesellschaft mbH, Burgdorf, Germany.
- f. Kardiacop 5 Monitor, Dateg-Ohmeda GmbH, Duisburg, Germany.
- g. Dobutamine Ratiopharm, Ratiopharm GmbH, Ulm, Germany.
- h. Ringer's solution, B. Braun Melsungen AG, Melsungen, Germany.
- i. Hemohep, B. Braun Melsungen AG, Melsungen, Germany.
- j. Euthadorm, CP-Pharma Handelsgesellschaft mbH, Burgdorf, Germany.
- k. Liquid DAB, Firma BioGenex, San Ramon, Calif.
- l. Anti-calprotectin, clone MAC387, monoclonal, mouse IgG1, DCS Diagnostik Systeme, Hamburg, Germany.
- m. Multilink antibody, Biologo, Steindamm, Germany.
- n. Super-Sensitive IM-Link-Label-Detection, Firma BioGenex, San Ramon, Calif.
- o. Image Pro Express Media Cybernetics Inc. Bethesda, Md.
- p. SAS, version 9.2, SAS Institute Inc, Cary, NC.
- q. Rathmanner M, Staszky C, Rötting AK, et al. Comparison of the inflammatory reaction in horses with and without development of post operative ileus (POI)(abstr), in *Proceedings. 20th Annu Sci Meet Eur Coll Vet Surg* 2011;57.
- r. Vente C. Intestinale Entzündungsreaktionen während Ischämie und Reperfusion im Jejunum des Pferdes unter besonderer Berücksichtigung der eosinophilen und neutrophilen granulozyten. Dr med vet dissertation, Tierärztliche Hochschule Hannover, Germany, 2011.

References

1. Freeman DE, Hammock P, Baker GJ, et al. Short- and long-term survival and prevalence of postoperative ileus after small intestinal surgery in the horse. *Equine Vet J* 2000;32:42–51.

2. Kalff JC, Schraut WH, Simmons RL, et al. Surgical manipulation of the gut elicits an intestinal muscularis inflammatory response resulting in postsurgical ileus. *Ann Surg* 1998;5:652–663.
3. Schwarz NT, Kalff JC, Türler A, et al. Selective jejunal manipulation causes postoperative pan-enteric inflammation and dysmotility. *Gastroenterology* 2004;126:159–169.
4. Hiki N, Simizu N, Yamaguchi H, et al. Manipulation of the small intestine as a cause of the increased inflammatory response after open compared with laparoscopic surgery. *Br J Surg* 2006;93:195–204.
5. The FO, Bennink RJ, Ankum WM, et al. Intestinal handling-induced mast cell activation in human postoperative ileus. *Gut* 2008;57:33–40.
6. De Jonge WJ, The FO, Ankum WM, et al. Mast cell degranulation during abdominal surgery initiates postoperative ileus in mice. *Gastroenterology* 2004;127:535–545.
7. Kalff JC, Turler A, Schwarz NT, et al. Intra-abdominal activation of a local inflammatory response within the human muscularis externa during laparotomy. *Ann Surg* 2003;237:301–315.
8. Hopster-Iversen C, Hopster K, Staszyc C, et al. Influence of mechanical manipulations on the local inflammatory reaction in the equine colon. *Equine Vet J Suppl* 2011;43:1–7.
9. Grisham MB, Granger DN. Neutrophil-mediated mucosal injury: role of reactive oxygen metabolites. *Dig Dis Sci* 1988;33:65–155.
10. Grisham MB, Gagginella TS, von Ritter C, et al. Effects of neutrophil-derived oxidants on intestinal permeability, electrolyte transport and epithelial cell viability. *Inflammation* 1990;14:531–542.
11. Schoenberg MH, Poch B, Younes M, et al. Involvement of neutrophils in postischaemic damage to the small intestine. *Gut* 1991;32:905–912.
12. Kubes P, Hunter J, Granger DN. Ischemia/reperfusion-induced feline intestinal dysfunction: importance of granulocyte recruitment. *Gastroenterology* 1992;103:807–812.
13. Moore RM, Bertone AL, Bailey MQ. Neutrophil accumulation in the large colon of horses during low-flow ischemia and reperfusion. *Am J Vet Res* 1994;55:1454–1463.
14. Gayle J, Jones SL, Argenzio RA, et al. Neutrophils increase paracellular permeability of restituted ischemic-injured porcine ileum. *Surgery* 2002;132:461–470.
15. Little D, Tomlinson JE, Blikslager AT. Post operative neutrophilic inflammation in equine small intestine after manipulation and ischaemia. *Equine Vet J* 2005;37:329–335.
16. Grosche A, Morton AJ, Polyak MMR, et al. Detection of calprotectin and its correlation to the accumulation of neutrophils within equine large colon during ischaemia and reperfusion. *Equine Vet J* 2008;40:393–399.
17. Faleiros RR, Macoris DG, Alves GES, et al. Local and remote lesions in horses subjected to small colon distension and decompression. *Can J Vet Res* 2008;72:68–76.
18. Rötting AK, Freeman DE, Constable PD, et al. Mucosal distribution of eosinophilic granulocytes within the gastrointestinal tract of horses. *Am J Vet Res* 2008;69:874–879.
19. Collobert-Laugier C, Hoste H, Sevin C, et al. Mast cell and eosinophil mucosal responses in the large intestine of horses naturally infected with cyathostomes. *Vet Parasitol* 2002;107:251–264.
20. Rötting AK, Freeman DE, Constable PD, et al. The effects of *strongylus vulgaris* parasitism on eosinophil distribution and accumulation in equine large intestinal mucosa. *Equine Vet J* 2008;40:379–384.
21. Rötting AK, Freeman D, Eurell JAC, et al. Effects of acetylcysteine and migration of resident eosinophils in an in vitro model of mucosal injury and restitution in equine right dorsal colon. *Am J Vet Res* 2005;64:1205–1212.
22. Hogan SP, Rosenberg HF, Moqbel R, et al. Eosinophils: biological properties and role in health and disease. *Clin Exp Allergy* 2008;38:709–750.
23. Luna LG. *Histopathologic methods and color atlas of special stains and tissue artifacts*. Gaithersburg, Md: American Histolab Inc, 1992;255–256.
24. Roussel AJ Jr, Cohen ND, Hooper RN, et al. Risk factors associated with development of postoperative ileus in horses. *J Am Vet Med Assoc* 2001;219:72–78.
25. Gerard MP, Blikslager AT, Roberts MC, et al. The characteristics of intestinal injury peripheral to strangulating obstruction lesions in the equine small intestine. *Equine Vet J* 1999;31:331–335.
26. Livingston EH, Passaro EP. Postoperative ileus. *Dig Dis Sci* 1990;35:121–132.
27. Kehlet H, Holte K. Review of postoperative ileus. *Am J Surg* 2001;182:35–105.
28. Barquist E, Bonaz B, Martinez V, et al. Neuronal pathways involved in abdominal surgery-induced gastric ileus in rats. *Am J Physiol* 1996;270:R888–R894.
29. Wehner S, Vilz TO, Stoffels B, et al. Immune mediators of postoperative ileus. *Langenbecks Arch Surg* 2012;397:591–601.
30. Boeckxstans GE, de Jonge WJ. Neuroimmune mechanisms in postoperative ileus. *Gut* 2009;58:1300–1311.
31. Ogilvy AJ, Smith G. The gastrointestinal tract after anaesthesia. *Eur J Anaesthesiol Suppl* 1995;10:35–42.
32. Köninger J, Gutt CN, Wente MN, et al. Postoperative ileus. Pathophysiology and prevention [in German]. *Chirurg* 2006;77:904–912.
33. Shippers E, Tittel A, Öttinger A, et al. Laparoscopy versus laparotomy: comparison of adhesion-formation after bowel resection in a canine model. *Dig Surg* 1998;15:145–147.
34. Gorvy DA, Edwards GB, Proudman CJ. Intra-abdominal adhesions in horses: a retrospective evaluation of repeat laparotomy in 99 horses with acute gastrointestinal disease. *Vet J* 2008;175:194–201.
35. Cook VL, Shults JJ, McDowell MR, et al. Anti-inflammatory effects of intravenously administered lidocaine hydrochloride on ischemia-injured jejunum in horses. *Am J Vet Res* 2009;70:1259–1268.