

Ultrasonographic measurement of abomasal volume, location, and emptying rate in calves

Thomas Wittek, Dr vet med; Peter D. Constable, BVSc, PhD; Tessa S. Marshall, BVSc, MS; Sonia S. Crochik, DVM, MS

Objective—To develop and validate an ultrasonographic method for measuring abomasal volume, location, and emptying rate in suckling calves.

Animals—9 male Holstein calves < 40 days of age.

Procedure—Before and after calves were fed different volumes of milk replacer or 2 L of oral electrolyte solutions, ultrasonographic measurements of abomasal dimensions (width, length, and height) were obtained by applying a 3.5-MHz sector probe to the ventral aspect of the abdomen in the transverse and sagittal planes. Abomasal volume was calculated from the ultrasonographic measurements by modeling the abomasum as an ellipsoid and by use of a power exponential equation to calculate the half-time of abomasal emptying ($t_{1/2}$).

Results—Preprandial abomasal volume was 20 to 137 mL. All 3 abomasal dimensions increased during feeding and after suckling, and the abomasum was symmetrically located about the midline of the ventral aspect of the abdomen. Strong linear relationships were identified between ultrasonographic and suckled volumes, between ultrasonographic and scintigraphic heights, and between ultrasonographic and scintigraphic lengths. Ultrasonographic $t_{1/2}$ was linearly related to scintigraphic $t_{1/2}$; the latter is regarded as the gold standard measure of gastric emptying rate.

Conclusions and Clinical Relevance—Ultrasonographic evaluation of the abomasum appears to provide a practical, rapid, noninvasive, and accurate method for determination of abomasal volume, location, and emptying rate in suckling calves. (*Am J Vet Res* 2005;66:537–544)

Abomasal volume is increased in calves with abomasal tympany,^{1,3} abomasal volvulus, left-displaced abomasum, and small intestinal obstruction,^{4,6} and the rate of abomasal emptying is believed to play an important role in the etiopathogenesis of abomasal disorders in calves. The abomasal emptying rate is also an important determinant of the rate of resuscitation in dairy calves with diarrhea. A practical, noninvasive, and rapid method for assessing abomasal volume, location, and

emptying rate in calves would therefore be clinically useful but is presently unavailable.

Methods for the ultrasonographic examination of the stomach and measurement of gastric volume and emptying rate have been developed and validated for adult⁷⁻¹² and infant humans.^{13,14} Methods for the ultrasonographic examination of the pyloric antrum¹⁵ and abomasal body¹⁶⁻²⁰ in adult bovids have been described, and a preliminary report of the ultrasonographic examination of the abomasum of calves exists.⁸ However, detailed reports on the use of ultrasonography to determine abomasal volume and emptying rate in adult cattle and suckling calves do not appear to be available. On the basis of results of ultrasonographic studies in infant^{13,14} and adult humans,^{11,12} we hypothesized that ultrasonographic measurement of abomasal dimensions would provide an accurate method for determining abomasal volume and position in suckling calves. We also hypothesized that monitoring the change in abomasal volume with time would provide an accurate method for determining the abomasal emptying rate in suckling calves. Accordingly, the purpose of the study reported here was to develop and validate an ultrasonographic method for measuring abomasal volume, location, and emptying rate in suckling calves.

Materials and Methods

Animals and instrumentation—This study was approved by the University of Illinois Institutional Animal Care and Use Committee. Nine healthy male Holstein-Friesian calves were obtained from the university dairy farm within the first week after their birth. Each calf had a cannula^b surgically placed in the abomasal body, as previously described.²¹ After the calves had recovered from surgery and anesthesia, they were kept unrestrained in individual stalls that were bedded with sawdust; calves were fed (60 mL/kg) twice a day with a medicated all milk-protein milk replacer^c (minimum crude protein, 20%; minimum crude fat, 20%; maximum crude fiber, 0.15%; minimum calcium, 0.5%; maximum calcium, 1.0%; minimum phosphorus, 0.6%; and decoquinate, 45.4 g/ton [providing 0.5 mg/kg of body weight]) and had access to fresh water at all times.

Experimental protocols—At least 2 days after surgical cannulation, at least 36 hours after completion of the previous ultrasonographic study, and at least 10 hours after the previous feeding of milk replacer, each calf was weighed and placed in a movable calf stall that allowed sitting and standing but prevented extensive lateral and forward movement. Calves were between 7 and 40 days of age when studied in 3 separate experiments.

Experiment 1—Calves (n = 6) aged 7 to 30 days were fed milk replacer in 250- or 500-mL increments (to a maximum total volume of 3 L) within a 15-minute period, and ultrasonographic measurements of abomasal dimensions were obtained. Suckling of each incremental volume required < 1 minute, and all ultrasonographic measurements were

Received March 22, 2004.

Accepted May 11, 2004.

From the Department of Veterinary Clinical Medicine, College of Veterinary Medicine, University of Illinois, Urbana, IL 61802. Dr. Wittek's present address is Medizinische Tierklinik der Universität Leipzig, An den Tierkliniken 11, 04103 Leipzig, Germany.

Supported by grants from the Max Kade Foundation (New York) and the USDA Hatch No. ILLU-70-0360.

The authors thank Beth Saupe, Stacy Furgang, and Dr. Ismail Sen for technical assistance.

Address correspondence to Dr. Constable.

obtained within 3 minutes after suckling each incremental volume. The incremental series of suckling episodes during experiment 1 was performed on 2 separate occasions for each calf, from which 10 to 14 sets of measurements for each calf were obtained (some calves did not suckle a total volume of 2.75 or 3.00 L on 1 or both occasions). All measurements were performed by the same investigator (TW).

Experiment 2—Calves (n = 6) aged 7 to 40 days were provided with 2 L of milk replacer or an iso-osmotic solution (150mM) containing NaCl, NaHCO₃, or sodium acetate,^d or 60 mL of milk replacer/kg. Ultrasonographic measurements of abomasal dimensions were obtained within 2 minutes after suckling. Each calf was fed and studied on 6 to 10 occasions separated by at least 36 hours, providing a total of 46 measurements. All measurements were performed by the same investigator (TW).

The coefficient of variation for ultrasonographic determination of abomasal volume was calculated from data obtained from the 5 of the 6 calves that were fed 2 L of milk replacer or the iso-osmotic solution on 4 separate days.

Experiment 3—Calves (n = 9) aged 7 to 30 days were provided with 2 L of milk replacer, fresh milk from Holstein cows, or an iso-osmotic solution (150mM) containing NaCl, NaHCO₃, or sodium acetate and 370 MBq of technetium Tc 99m diethylenetriamine-pentaacetic acid. Scintigraphy was performed and ultrasonographic measurements of abomasal dimensions were obtained immediately after suckling and at intervals for 4 hours (ie, at 10, 20, 30, 45, 60, 90, 120, 150, 180, and 240 minutes) after the start of suckling, with ultrasonography performed immediately after scintigraphy.

Ultrasonographic determination of abomasal dimensions, area, and volume—For ultrasonographic evaluation, the hair on the ventral aspect of the abdomen of each calf was clipped. Each calf was gently restrained in a standing position, and a 3.5-MHz ultrasound sector or linear array probe^c was applied to the abdomen in transverse and sagittal planes to determine the maximal ultrasonographically visible abomasal dimensions (length, width, and height). A flexible cloth tape was used to facilitate measurement of those dimensions. The distance between the cranial edge of the abomasum and the xiphoid process and the distance between the caudal edge of the abomasum and the xiphoid process were determined, and the abomasal length calculated by subtraction (Figure 1). Therefore, abomasal length was defined as the maximal dimension in the axial plane, the width was defined as the sum of the maximal dimensions in the left and right lateral planes, and the height was defined as the maximal dimension in the dorsal plane. All measurements were from serosal surface to serosal surface of the abomasum.

Because the abomasum of a calf attains an ellipsoidal shape after suckling,²²⁻²⁶ the abomasal area in the horizontal plane was calculated by use of an equation for calculation of the area of an ellipse (ie, horizontal area = width × length × π/4, where the constant π is an irrational number [approx 3.142]). Abomasal volume was calculated by use of an equation for calculation of the volume of an ellipsoid (ie, volume = width × length × height × π/6).

Ultrasonographic determination of abomasal emptying rate—Two equations were

used to calculate the abomasal emptying rate from the measurements of abomasal volume with time. Both equations incorporated individual variations in emptying pattern and described an early lag phase and slow late phase of emptying after ingestion,²⁷ both of which are detected in suckling calves.²⁸

The first equation was the power exponential equation of Elashoff et al.²⁷ A volume-versus-time curve was generated for each experiment, and the power exponential equation was used to fit a modeled curve to the data as follows:

$$y(t) = 2^{-(\text{time}/T50)^\beta} \quad (1)$$

where y(t) is the proportion of the peak volume remaining after suckling, time is the time interval from the start of suckling in minutes, T50 is the time interval required for the initial radioactivity level to decrease by 50%, and β is a constant that determines the shape of the curve. The highest value for the volume after suckling was set at 1.00; if volume before the time of highest volume was < 1.00, then the volume at that time point was set to 1.00.^{27,29}

The second equation was a modified power exponential equation of Siegel et al.³⁰ A volume-versus-time curve was generated for each experiment as follows:

$$y(t) = 1 - (1 - e^{-k_u \cdot \text{time}})^{\beta_u} \quad (2),$$

where y(t) is the proportion of peak volume remaining after suckling, time is the time interval from the start of suckling in minutes, the constant e is an irrational number (approx 2.718), k_u is the abomasal emptying rate (min⁻¹), and β_u is the extrapolated y-intercept for the terminal portion of the curve (β_u > 1 indicates an initial delay in emptying; β_u < 1 indicates an initial rapid emptying). Compared with equation 1, the major advantage of equation 2 is that it characterizes the duration of the lag phase in minutes, instead of a nondimensional number.³⁰ By use of the values for k_u and β_u obtained from nonlinear regression analysis of experimental data, we calculated the ultra-

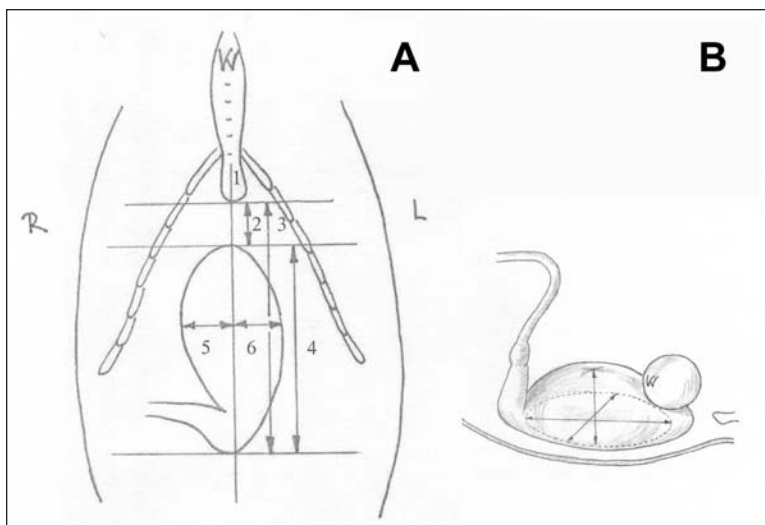


Figure 1—Illustrations of the measurement of abomasal surface projection in suckling calves. A—Ventral view of the abdominal region of a calf (Adapted from Kurosawa et al¹⁶ and Braun et al.¹⁸ Reprinted with permission). R and L = Right and left sides of the calf. 1 = Xiphoid process. 2 = Cranial margin of the abomasum. 3 = Caudal margin of the abomasum. 4 = Length of the abomasum. 5 = Width of the abomasum to the right of midline of the abdomen. 6 = Width of the abomasum to the left of midline of the abdomen. B—Right lateral view of the abdominal region of a calf with the head of the calf toward the right.

sonographic half-time of abomasal emptying ($t_{1/2}$) as follows³⁰:

$$\text{Ultrasonographic } t_{1/2} = (-1/k_u) \cdot \log_e(1 - 2^{-1/\beta_u}), \quad (3)$$

where \log_e is the natural logarithm with base e.

Scintigraphic determination of abomasal dimensions and emptying rate—Scintigraphic images were obtained by use of a parallel-hole, low-energy, all-purpose gamma camera.^f The gamma camera was positioned for acquisition of dorsal and right lateral images. Dorsal images were obtained in a dynamic study during suckling to assist in identifying the anatomic location of the abomasum and monitor the route of the suckled fluid, thereby ensuring that esophageal groove closure had occurred. For the dorsal image, a matrix size of 64×64 was used and data for the dynamic study during suckling were collected for 40 frames at 3 s/frame. For the right lateral view, a matrix size of 64×64 was used and data were collected for 1 frame at 30 s/frame to monitor the rate of abomasal emptying and measure abomasal dimensions (height and length) after suckling.

A nuclear medicine software program^g was used to define the abomasum as the region of interest (ROI) in the right lateral static image. The static image intensity was adjusted to the hot-body color scale for the software program, and the lower level window was set at approximately -1,300. The upper level window was then set to approximately 1,320 so that saturation was not evident in the first image obtained after suckling. The ROI was drawn by use of the irregular option in the software program, thereby tracing the outline of the abomasum in an objective manner. The pyloric antrum was not included in the ROI because initially this region was unidentifiable, whereas towards the end of the experiment the pyloric antrum was sometimes identifiable but was usually superimposed on the image of the small intestine. The total numbers of counts in the ROI recorded during each 30-second data collection period were then determined and corrected for decay to that obtained in the immediate postsuckling image.

An activity-versus-time curve was generated for the ROI in each experiment by use of the modified power exponential formula of Siegel et al³⁰:

$$y(t) = 1 - (1 - e^{[-k_s \cdot \text{time}]})^{\beta_s}, \quad (4)$$

where $y(t)$ is the proportion of peak radioactivity after suckling at time t (the time interval from the start of suckling in minutes), the constant e is an irrational number (approx 2.718), k_s is the abomasal emptying rate (min^{-1}), and β_s is the

extrapolated y -intercept for the terminal portion of the curve. The highest value for radioactivity after suckling was set at 1.00; if radioactivity before the time of highest volume was less than the peak value, then y at that time was set to 1.00.^{27,29} By use of the values for k_s and β_s obtained from nonlinear regression analysis of experimental data, we calculated the scintigraphic $t_{1/2}$ as follows³⁰:

$$\text{Scintigraphic } t_{1/2} = (-1/k_s) \cdot \log_e(1 - 2^{-1/\beta_s}). \quad (5)$$

Statistical analyses—Data were expressed as mean and SD; a value of $P < 0.05$ was considered significant. A statistical software program^h was used for all statistical analyses.

Nonlinear regression analysis was used to calculate ultrasonographic T50 (equation 1), ultrasonographic $t_{1/2}$ (equation 3), and scintigraphic $t_{1/2}$ (equation 5). The best-fitting equation for the ultrasound data (equation 1 or 3) was selected on the basis of the lowest Akaike information criterion value^{31,h} and findings of visual examination of plots of observed and predicted values against time and examination of residual plots.

Multivariable regression analysis^h was used to determine the linear association between ultrasonographic volume and fed volume (experiments 1 and 2), between ultrasonographic $t_{1/2}$ and scintigraphic $t_{1/2}$ (experiment 3), and between ultrasonographic dimensions and scintigraphic dimensions (experiment 3); in all analyses, a dummy variable coding for each calf, which accounted for between-calf variability, was used, thereby increasing the precision with which slope and intercept coefficients for the regression

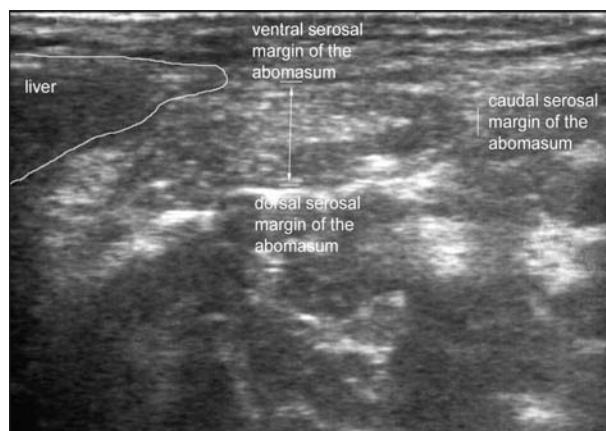


Figure 2—Sagittal ultrasonographic view of the abdomen of a calf before suckling. Notice that the abomasum is small, and its dorsal, ventral, and caudal margins can be clearly identified.

Table 1—Abomasal dimensions (mean \pm SD) measured ultrasonographically in 6 calves during feeding with milk replacer in 250- or 500-mL increments (to a total volume of 3 L) on 2 occasions each.

Suckled volume (mL)	Length (cm)	Width to left of midline (cm)	Width to right of midline (cm)	Width (total [cm])	Height (cm)
0	6.8 \pm 2.6	3.0 \pm 1.0	2.0 \pm 1.2	5.0 \pm 1.0	3.3 \pm 0.7
500	9.4 \pm 1.9	5.8 \pm 1.3	6.0 \pm 1.1	11.9 \pm 2.0	6.7 \pm 1.5
750	12.3 \pm 3.9	5.8 \pm 1.1	6.3 \pm 1.4	12.0 \pm 2.5	7.4 \pm 0.7
1,000	13.0 \pm 2.8	7.7 \pm 1.6	7.9 \pm 1.9	15.7 \pm 3.5	8.4 \pm 1.5
1,250	14.8 \pm 2.4	7.9 \pm 1.4	8.0 \pm 1.0	15.9 \pm 2.3	8.6 \pm 0.7
1,500	16.7 \pm 1.0	8.0 \pm 1.8	8.7 \pm 1.3	16.7 \pm 2.8	9.1 \pm 0.4
1,750	17.2 \pm 2.8	9.8 \pm 1.9	9.5 \pm 1.6	19.3 \pm 3.3	9.9 \pm 0.8
2,000	16.7 \pm 3.5	10.2 \pm 1.5	10.3 \pm 1.9	20.5 \pm 3.3	10.6 \pm 1.2
2,250	18.4 \pm 3.1	10.4 \pm 1.6	10.1 \pm 1.1	20.5 \pm 2.4	11.0 \pm 1.2
2,500	20.1 \pm 2.4	10.1 \pm 1.2	10.9 \pm 1.6	21.0 \pm 2.7	10.7 \pm 1.0
2,750	20.3 \pm 2.9	11.3 \pm 1.0	10.9 \pm 1.2	22.2 \pm 2.1	11.9 \pm 0.9
3,000	19.3 \pm 4.1	12.0 \pm 0.7	11.6 \pm 1.4	23.6 \pm 2.1	12.4 \pm 1.4

line were estimated.³¹ This analysis of covariance approach enforces a uniform slope but different intercept value for each calf; this approach is appropriate whenever the slopes are similar,³² as in this study. Dummy variables (C_i through C_n) were defined as follows:

$$C_i = 1 \text{ if calf } i (i < n), -1 \text{ if calf } = n, \text{ and } 0 \text{ otherwise.}$$

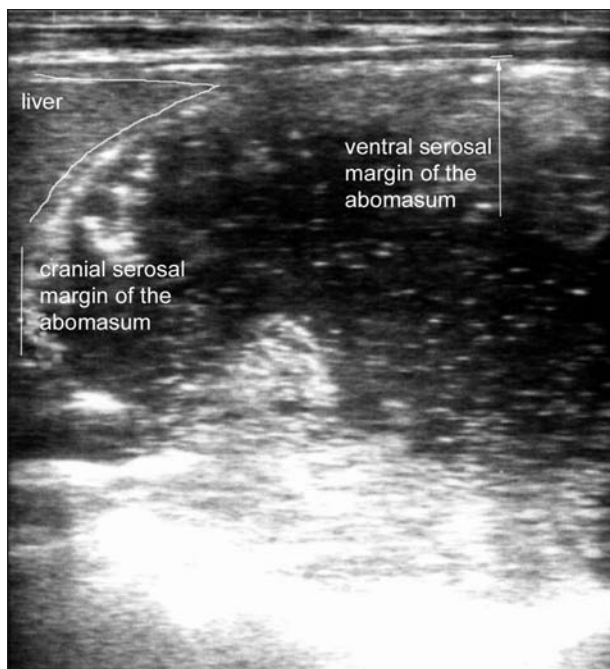


Figure 3—Sagittal ultrasonographic view of the abdomen of the calf in Figure 2 after suckling. Notice that the abomasum is much larger than it appeared before suckling, and only the ventral and cranial margins of the abomasum can be clearly identified in this view.

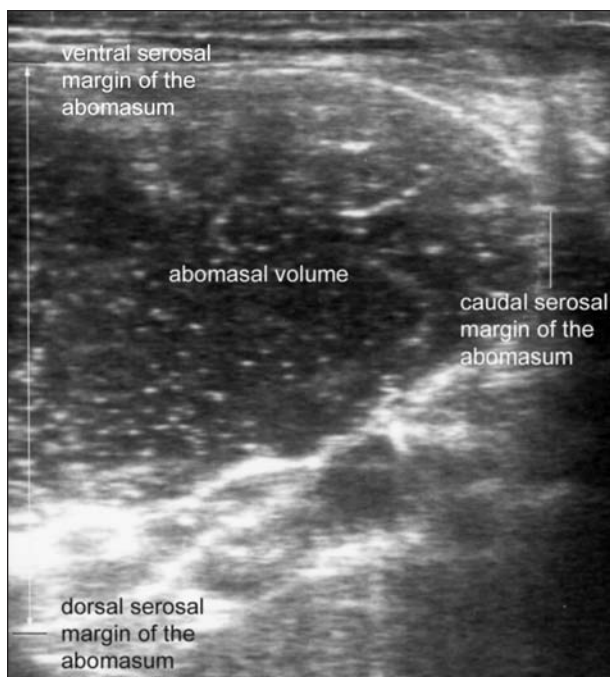


Figure 4—Sagittal ultrasonographic view of the abdomen of a calf after suckling. Notice that the abomasum is much larger than it appears in Figure 2, and the ventral, dorsal, and caudal margins of the abomasum can be clearly identified in this view.

The linear relationship between the dependent variable (y) and suckled volume was analyzed as follows:

$$y = b_o + \sum b_i \cdot C_i + b_v \cdot (\text{suckled volume}),$$

where b_o is the intercept value, b_i is the coefficient value for i th calf, and b_v is the coefficient value for suckled volume. Dummy variables were entered into the model first to account for between-calf differences before analyzing the main factor of interest. Coefficients associated with C_i described how much the intercept values for each calf varied from the mean, but this information was of minimal interest in this study, and only the coefficients for b_o and b_v are reported. The adequacy of the final regression model was evaluated via examination of residual plots and the normal probability plot of the standardized residuals, and the presence of outliers or influential observations were identified by calculating Cook's distance.^{31,b}

Results

Six calves were studied in experiment 1, 6 calves were studied in experiment 2, and 9 calves were studied in experiment 3.

Experiment 1—In the 6 calves examined ultrasonographically, preprandial and postprandial ultrasonographic images were obtained and abomasal dimensions assessed (Figures 2–4). Preprandial abomasal volume ranged from 20 to 137 mL (mean, 62 mL), and preprandial area of the ventral aspect of the abomasum ranged from 11 to 50 cm² (mean, 27 cm²). All 3 abomasal dimensions increased during feeding, and the abomasum was symmetrically located about the midline of the ventral aspect of the abdomen (Table 1).

A strong linear relationship ($R^2 = 0.97$; $P < 0.001$) was identified between ultrasonographic volume and suckled volume during incremental feeding (Figure 5). Multivariable regression analysis revealed a relationship between ultrasonographic volume and suckled volume (volumes given in mil-

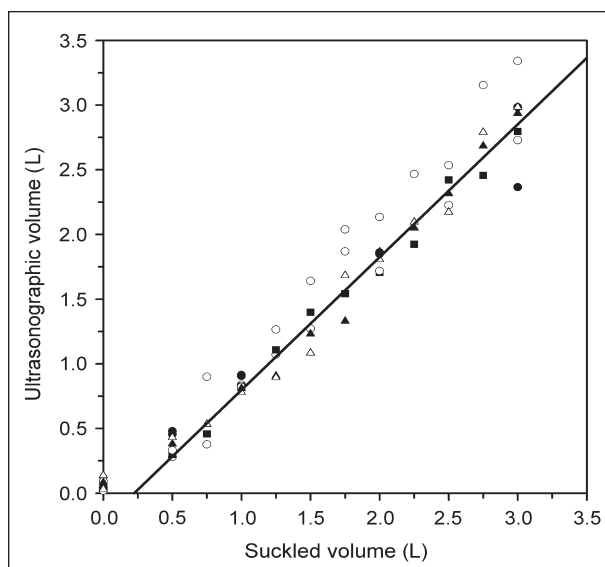


Figure 5—Scatterplot describing the relationship between ultrasonographically calculated abomasal volume and suckled volume after incremental feeding of milk replacer in 6 male calves (each represented by different symbols). The solid line is the calculated linear regression line.

liliters with values of SEM in parentheses) as follows:

$$\text{Ultrasonographic volume} = 1.027(0.027) \cdot (\text{suckled volume}) - 181(51).$$

The coefficient value did not differ from 1 ($P = 0.31$), but the intercept value was < 0 ($P < 0.001$).

The R^2 value (0.92; $P < 0.001$) for the linear relationship between horizontal ultrasonographic area and suckled volume was less than that for the linear relationship between ultrasonographic volume and suckled volume, indicating that ultrasonographic measure-

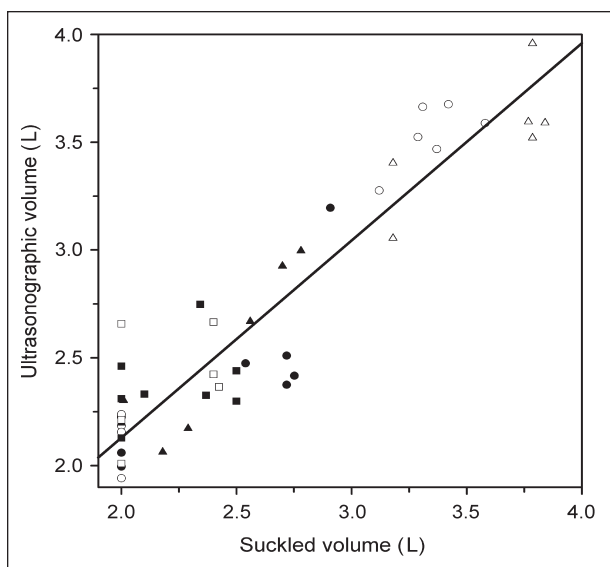


Figure 6—Scatterplot describing the relationship between ultrasonographically calculated abomasal volume and suckled volume after feeding 2 L of milk replacer or 60 mL of milk replacer/kg body weight in 6 male calves (each represented by different symbols). The solid line is the calculated linear regression line.

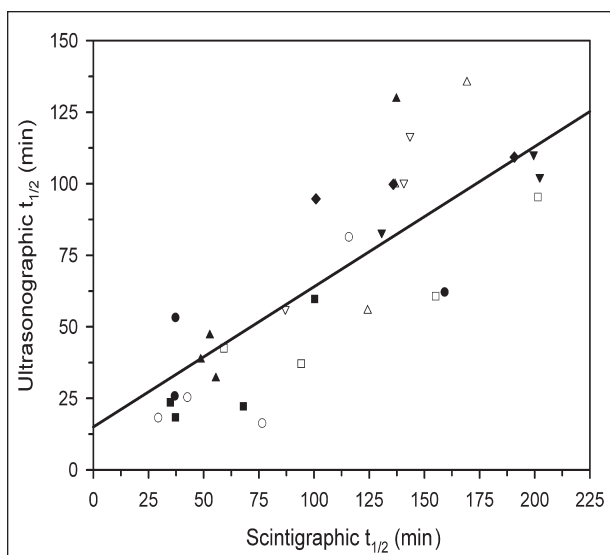


Figure 7—Scatterplot describing the relationship between ultrasonographically and scintigraphically calculated half-time of abomasal emptying ($t_{1/2}$) in 9 male calves (each represented by different symbols). The solid line is the calculated linear regression line.

ment of 3 dimensions (length, width, and height) had greater explanatory power. Multivariable regression analysis revealed a relationship between horizontal ultrasonographic area (given in centimeters²) and suckled volume (given in milliliters with values of SEM in parentheses) as follows:

$$\text{Ultrasonographic area} = 0.110(0.005) \cdot (\text{suckled volume}) + 52(12).$$

The intercept value was > 0 ($P < 0.001$).

Experiment 2—From analysis of data obtained from 6 calves, a linear relationship ($R^2 = 0.89$; $P < 0.001$) between measured and suckled volume was identified during feeding of 2 L of milk replacer or 60 mL of milk replacer/kg of body weight (Figure 6). Multivariable regression analysis revealed a relationship between ultrasonographic volume and suckled volume (volumes given in milliliters with SEM in parentheses) as follows:

$$\text{Ultrasonographic volume} = 0.915(0.079) \cdot (\text{suckled volume}) + 299(207).$$

The coefficient and intercept values did not differ from 1 ($P = 0.28$) and 0 ($P = 0.16$), respectively, indicating that the regression line was similar to the line of identity.

The coefficient of variation for ultrasonographic measurement of abomasal volume after suckling 2 L of milk replacer or an iso-osmotic solution ranged from 3.1% to 17.4%, with a mean value of 7.7% for 5 calves.

Experiment 3—The best-fitting equation for determining abomasal emptying rate from ultrasonographic data was equation 2, on the basis of the Akaike information criterion value, findings of visual examination of plots of observed-versus-predicted concen-

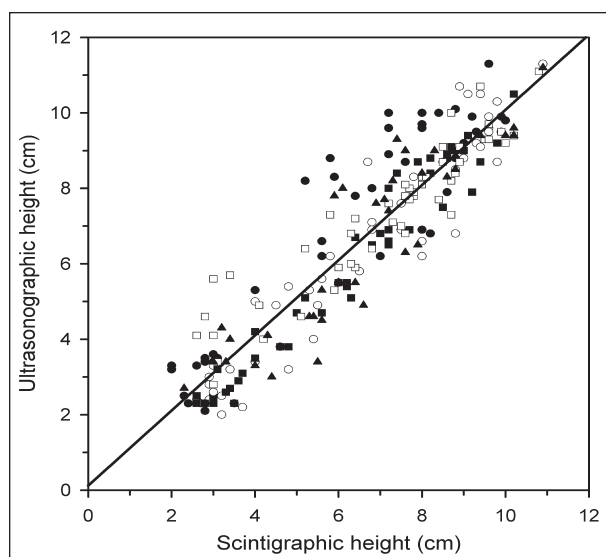


Figure 8—Scatterplot describing the relationship between ultrasonographically and scintigraphically determined abomasal height in 5 male calves (each represented by different symbols). The solid line is the calculated linear regression line.

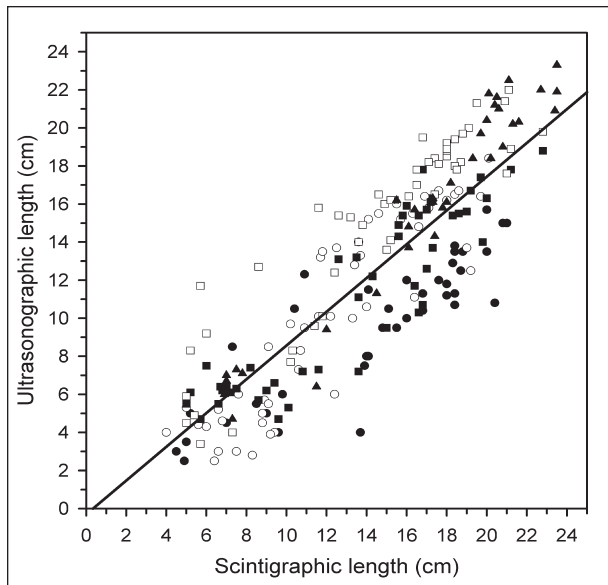


Figure 9—Scatterplot describing the relationship between ultrasonographically and scintigraphically determined abomasal length of 5 male calves (each represented by different symbols). The solid line is the calculated linear regression line.

trations and examination of residual plots, and ease in converging to a solution.

A linear relationship ($R^2 = 0.81$; $P = 0.009$) was identified between ultrasonographic $t_{1/2}$ and scintigraphic $t_{1/2}$ (Figure 7). Linear regression analysis revealed a relationship between ultrasonographic $t_{1/2}$ and scintigraphic $t_{1/2}$ (values given in minutes with SEM in parentheses) as follows:

$$\text{Ultrasonographic } t_{1/2} = 0.490(0.091) \cdot (\text{scintigraphic } t_{1/2}) + 15.0(10.6).$$

The coefficient value was different from 1 ($P < 0.001$), whereas the intercept value did not differ from 0 ($P = 0.17$).

A linear relationship ($R^2 = 0.89$; $P < 0.001$) was identified between ultrasonographic height and scintigraphic height (Figure 8). Linear regression analysis revealed a relationship between ultrasonographic height and scintigraphic height (values given in centimeters with SEM in parentheses) as follows:

$$\text{Ultrasonographic height} = 0.996(0.025) \cdot (\text{scintigraphic height}) + 0.121(0.160).$$

The coefficient value did not differ from 1 ($P = 0.88$), and the intercept value did not differ from 0 ($P = 0.48$), indicating that the regression line was similar to the line of identity.

A linear relationship ($R^2 = 0.86$; $P < 0.001$) was identified between ultrasonographic length and scintigraphic length (Figure 9). Linear regression analysis revealed a relationship between ultrasonographic length and scintigraphic length (values given in centimeters with SEM in parentheses) as follows:

$$\text{Ultrasonographic length} = 0.887(0.028) \cdot (\text{scintigraphic length}) - 0.306(0.417).$$

The coefficient value was < 1 ($P < 0.001$), whereas the intercept value did not differ from 0 ($P = 0.46$), indicating that scintigraphic length was slightly greater than ultrasonographic length.

Discussion

The major findings of the present study were that ultrasonographic measurement of abomasal dimensions in suckling calves provided an accurate method of determining abomasal volume and location and a useful index of abomasal emptying rate. In particular, the dimensions of a calf's abomasum after suckling a known volume can be used clinically to determine whether the abomasum is displaced from its normal location on the midline of the ventral aspect of the abdomen and whether the abomasum is distended. This information can be useful in deciding whether surgery is indicated in preruminant calves, particularly when the volume and time of the last milk meal are known.

Abomasal position in suckling calves has been determined at necropsy^{33,34} by examination of dorsoventral radiographic views of the abdomen²⁵ and by examination of lateral radiographic views of the abdomen after ingestion of a meal containing barium sulfate.²²⁻²⁴ The results of these studies have suggested that the abomasum of the neonatal calf is situated primarily on the abdominal floor immediately ventral to the rumen, reticulum, and omasum and that after suckling a milk meal, the abomasal body expands caudally and laterally with relatively little increase in its dimension dorsally to occupy most of the abdominal cavity from the diaphragm to the fifth lumbar vertebra. Our ultrasonographic and scintigraphic findings were similar to those obtained in other studies; however, Lagerlöf³³ stated that the abomasum distended slightly more to the left than the right of the ventral portion of the abdomen after suckling, whereas radiography performed with calves in sternal recumbency²⁵ revealed that the abomasum distended more to the right after suckling. We identified a symmetric lateral expansion of the abomasum from the midline of the ventral aspect of the abdomen but cannot rule out the possibility that the presence of the abomasal cannula on the right flank of the abdomen may have slightly restricted leftwards expansion of the abomasum.

Our data indicated that the relationship between ultrasonographic and scintigraphic height measurements fitted the line of identity; however, scintigraphic length measurements were slightly longer than ultrasonographic length measurements. The latter finding was attributed to slight forward and backward movement of the standing calf during each 30-second scintigraphic recording. Alternatively, ultrasonography may underestimate the true length of the abomasum; support for this possibility was provided via analysis of the results of the incremental feeding study (experiment 1), which revealed that the intercept value for the linear relationship was < 0 , indicating a slight underestimation of the abomasal volume when calculated from ultrasonographic dimensions. However, it is probable that some of the suckled volume had already emptied from the abomasum during the 15-minute period

required to measure abomasal dimensions in experiment 1. When ultrasonographic measurements were obtained within 3 minutes of suckling (experiment 2), the intercept value for the linear relationship was not significantly different from 0.

The first ultrasonographic method for measuring gastric volume in humans was developed in 1982 and involves consecutive cross-sectional images of the filled stomach^{8,9}; the stomach volume is calculated by performing consecutive ultrasonographic investigations of the stomach in 1-cm parallel cross-sectional slices along the longitudinal axis. Each section volume is calculated by use of the equation for the volume of a cylinder (assuming the cross sections were circular), and the section volumes are summated to calculate the total gastric volume. This ultrasonographic method is tedious and time consuming¹¹ and requires a cooperative patient so that the stomach is completely visible in each cross-sectional image. Therefore, the method was not suitable for measuring abomasal volume in calves. A simplified ultrasonographic method for measuring gastric volume in humans was developed in 1985,¹⁰ in which the area of the pyloric antrum (**antral cross-sectional area [ACSA]**) is used instead of the summated gastric volumes for estimation of total gastric volume. In the ACSA method, the superior mesenteric artery and vein, vertebrae, or aorta are used as anatomic landmarks to enable sequential examination of the same antral section; however, this method also requires a cooperative patient and was therefore not suitable for use in calves. Moreover, because it is clinically valuable to identify the anatomic position of the abomasum within the abdomen in calves, the ACSA method does not appear to be the best method of assessment because it does not provide information on abomasal dimensions and location.

To our knowledge, this was the first application of ultrasonography to measure gastric emptying rate in domestic animals. By use of the new technique, the abomasal dimensions were measured and the abomasal body was modeled as an ellipsoid. A review of the literature^{22,23,33} and the results of experiments 1, 2, and 3 of the present study indicated that this modeling assumption was reasonable. This modeling approach disregards the volume of the pyloric antrum, but this part of the abomasum has a relatively small volume, compared with the abomasal body after the calf suckles a high-volume meal.²²⁻²⁴ The data obtained in experiments 1 and 2 indicated that the slope of the relationship between ultrasonographic volume and suckled volume was not significantly different from 1, which strongly supports the validity of our modeling assumption. Although all measurements were performed in experiments 1 and 2 by the same investigator (TW), the ultrasonographic technique is straightforward and simple to learn and apply. It is our opinion that the approach will be accurate when applied by different investigators because the results of a gastric-emptying study³⁵ in humans indicated the Pearson correlation coefficient between 2 ultrasonographic observers was 0.83. Moreover, the mean coefficient of variation for 5 calves each suckling a 2-L volume was 7.7% in our study; this value was similar to that of the ACSA

method in infant humans (7.7%).³⁶ We do not believe that the presence of an abomasal cannula altered emptying rate in the study calves because the placement of a percutaneous endoscopic gastrostomy tube does not slow gastric emptying in cats³⁷; furthermore, compared with an abomasal cannula, the presence of a much more invasive duodenal reentrant cannula does not alter emptying rate in milk-fed calves.³⁸

Ultrasonographic measurements indicate the change in stomach volume with time, whereas scintigraphic measurements indicate the rate of disappearance of a radioactive agent from the stomach.¹¹ At any time, the abomasal volume in calves is the sum of the preprandial volume, suckled volume, and volume of fluids secreted by the salivary glands and abomasum, minus the volume emptied from the abomasum. In experiment 1, it was determined that the preprandial volume was small (20 to 137 mL); thus, disregarding the contribution of preprandial volume in calculation of the abomasal volume would result in only a small error. However, during a 12-hour period, the secreted volume is not inconsequential (mean volume, 42 mL/kg of body weight in milk-fed calves³⁹ and 28 mL/kg of body weight in calves from which food was withheld⁴⁰), compared with the suckled volume of 60 mL/kg of body weight. Therefore, the secreted volume contributes substantially to the ultrasonographic volume. Because the emptying rate of the radioactive agent from the abomasum is assessed scintigraphically, emptying curves constructed from scintigraphic and ultrasonographic data (and the calculated $t_{1/2}$) would be expected to differ, particularly when a nonliquid meal is ingested, or secreted volumes would differ because of differences in the formulation of the ingested meal. Our finding that the ultrasonographic $t_{1/2}$ was shorter than the scintigraphic $t_{1/2}$ was similar to that obtained in a study¹² of the emptying rate of liquids from the stomach in humans.

Nuclear scintigraphy is widely regarded as the gold standard method for assessing gastric emptying because it provides an accurate, quantitative, and sensitive method.⁴¹ A linear relationship ($R^2 = 0.69$) between ultrasonographic measurements of gastric emptying rate and scintigraphically determined emptying rate has been reported in humans.¹¹ In the present study, the comparison of the ultrasonographically estimated abomasal emptying rate in calves with the scintigraphic measurements of emptying rate revealed a good linear relationship ($R^2 = 0.80$) between ultrasonographic $t_{1/2}$ and scintigraphic $t_{1/2}$. We believe that a stronger linear relationship between the 2 factors was prevented by dietary-induced variations in the volume of salivary and abomasal secretions.

On the basis of the results of our study, we conclude that ultrasonographic measurement of abomasal dimensions provides an accurate estimate of abomasal volume and position in suckling calves. Additionally, ultrasonography provides a practical, rapid, noninvasive, and reasonably accurate method for determining abomasal emptying rate in calves. Ultrasonographic evaluation avoids the administration of marker substances (such as radioactive agents or acetaminophen) that may not be permitted in food-producing animals

in some countries. However, because abomasal volume depends on the volume of salivary and abomasal secretions and the rate of abomasal emptying, ultrasonographic determination of emptying rate in suckling calves will be most accurate when a standard meal is fed to ensure repeatable salivary and abomasal secretion rates.

- a. Sakai J, Kato T, Sako T, et al. Measurement of abomasal emptying rate with ultrasonic and acetaminophen methods in suckling calves (abstr). *Vet Radiol* 1994;35:244.
- b. Percutaneous endoscopic gastrostomy kit, MILA Instruments Inc, Florence, Ky.
- c. Agri Master, Supreme All Milk, Blain Supply, Janesville, Wis.
- d. Sigma Aldrich, St Louis, Mo.
- e. Ultramark 4, Advanced Technology Laboratories, Tempe, Ariz.
- f. Technicare Omega 500, Technicare Corp, Cleveland, Ohio.
- g. Alfamark IM512P, MEDX, Arlington Heights, Ill.
- h. SAS 8e, SAS Institute Inc, Cary, NC.

References

1. Roeder BL, Chengappa MM, Nagaraja TG, et al. Isolation of *Clostridium perfringens* from neonatal calves with ruminal and abomasal tympany, abomasitis, and abomasal ulceration. *J Am Vet Med Assoc* 1987;190:1550-1555.
2. Roeder BL, Chengappa MM, Nagaraja TG, et al. Experimental induction of abomasal tympany, abomasitis, and abomasal ulceration by intraruminal inoculation of *Clostridium perfringens* type A in neonatal calves. *Am J Vet Res* 1988;49:201-207.
3. Kümper H. A new treatment for abomasal tympany in calves. *Tierarztl Prax* 1994;22:25-27.
4. Dirksen G. Present state of diagnosis, treatment and prophylaxis of left displacement of bovine abomasum. *Dtsch Tierarztl Wochenschr* 1967;74:625-633.
5. Dennis R. Abomasal displacement and tympany in a nine-week old calf. *Vet Rec* 1984;14:218-219.
6. Dirksen G. Differentialdiagnostik und Therapie von Vormagen—und Labmagenerkrankungen bei Kalb und Jungrind. *Prakt Tierarztl Collegium Veterinarium* 1987;XVIII:92-96.
7. Holt S, McDicken WN, Anderson T, et al. Dynamic imaging of the stomach by real-time ultrasound—a method for the study of gastric motility. *Gut* 1980;21:597-601.
8. Batemen DN, Whittingham TA. Measurement of gastric emptying by real-time ultrasound. *Gut* 1982;23:524-527.
9. Whittingham TA, Batemen DN. Measurement of stomach volume by real-time ultrasound. *Ultrasound Med Biol* 1983;suppl 2:459-463.
10. Bolondi L, Bortolotti M, Santi V, et al. Measurement of gastric emptying time by real-time ultrasonography. *Gastroenterology* 1985;89:752-759.
11. Holt S, Cervantes J, Wilkinson AA, et al. Measuring gastric emptying rate in humans by real-time ultrasound. *Gastroenterology* 1986;90:918-923.
12. Marzio L, Giacobbe A, Conoscitore P, et al. Evaluation of the use of ultrasonography in the study of liquid gastric emptying. *Am J Gastroenterol* 1989;84:496-500.
13. Cucchiaria S, Minella R, Iorio R, et al. Real-time ultrasound reveals gastric motor abnormalities in children investigated for dyspeptic symptoms. *J Pediatr Gastroenterol Nutr* 1995;21:446-453.
14. McClure RJ, Newell SJ. Effect of fortifying breast milk on gastric emptying. *Arch Dis Child* 1996;74:F60-F62.
15. Malbert C, Ruckebusch Y. Exploration fonctionnelle de l'antre pylorique chez les bovins par échotomographie. *Rev Med Vet* 1985;136:103-108.
16. Kurosawa T, Yagisawa K, Yamaguchi K, et al. Ultrasonographic observations of experimental traumatic reticuloperitonitis. *J Vet Med Sci* 1991;53:143-145.
17. Winter T, Hofmann W. Sonography as a tool in the diagnosis of displacement of the abomasum. *Tierarztl Prax* 1996;24:243-247.
18. Braun U, Wild K, Guscetti F. Ultrasonographic examination of the abomasum of 50 cows. *Vet Rec* 1997;140:93-98.
19. Braun U, Pusterla N, Schönmann M. Ultrasonographic findings in cows with left displacement of the abomasum. *Vet Rec* 1997;141:331-335.
20. van Winden SCL, Brattinga CR, Müller KE, et al. Position of the abomasum in dairy cows during the first six weeks after calving. *Vet Rec* 2002;151:446-449.
21. Ahmed AF, Constable PD, Misk NA. Effect of orally administered cimetidine and ranitidine on abomasal luminal pH in clinically normal milk-fed calves. *Am J Vet Res* 2001;62:1531-1538.
22. Benzie D, Phillipson AT. *The alimentary tract of the ruminant*. London: Oliver & Boyd, 1957;1-36.
23. Mylrea PJ. Digestion in young calves fed whole milk *ad lib*. and its relationship to calf scours. *Res Vet Sci* 1966;7:407-416.
24. Bell FR, Holbrooke SE, Titchen DA. A radiological study of gastric (abomasal) emptying in calves before and after vagotomy. *J Physiol* 1977;272:481-493.
25. Thompson SMR, Black WD. A study of the influence of the method of oral administration of ampicillin upon plasma drug levels in calves. *Can J Comp Med* 1978;42:255-259.
26. Nappert G, Lattimer JC. Comparison of abomasal emptying in neonatal calves with a nuclear scintigraphic procedure. *Can J Vet Res* 2001;65:50-54.
27. Elashoff JD, Reedy TJ, Meyer JH. Analysis of gastric emptying data. *Gastroenterology* 1982;83:1306-1312.
28. Bell FR, Razig SAD. Gastric emptying and secretion in the milk-fed calf. *J Physiol* 1973;228:499-512.
29. Collins PJ, Horowitz M, Shearman DJC, et al. Correction for tissue attenuation in radionuclide gastric emptying studies: a comparison of a lateral image method and a geometric mean method. *Br J Radiol* 1984;57:689-695.
30. Siegel JA, Urbain JLC, Adler LP, et al. Biphasic nature of gastric emptying. *Gut* 1988;29:85-89.
31. Glantz SA, Slinker BK. *Primer of applied regression and analysis of variance*. New York: McGraw-Hill Book Co, 1990;1-760.
32. Feldman HA. Families of lines: random effects in linear regression analysis. *J Appl Physiol* 1988;64:1721-1732.
33. Lagerlöf N. Investigations of the topography of the abdominal organs in cattle, and some clinical observations and remarks in connection with the subject. *Scandinavisk Veterinartidskrift* 1929;19:253-365.
34. Grossman JD. Form, development, and topography of the stomach of the ox. *J Am Vet Med Assoc* 1949;114:416-418.
35. Irvine EJ, Tougas G, Lappalainen R, et al. Reliability and interobserver variability of the ultrasonographic measurement of gastric emptying rate. *Dig Dis Sci* 1993;38:803-810.
36. Newell SJ, Chapman S, Booth IW. Ultrasonic assessment of gastric emptying in the preterm infant. *Arch Dis Child* 1993;69:32-36.
37. Smith SA, Ludlow CL, Hoskinson JJ, et al. Effect of percutaneous endoscopic gastrostomy on gastric emptying in clinically normal cats. *Am J Vet Res* 1998;59:1414-1416.
38. Sissons JW, Smith RH. Effect of duodenal cannulation on abomasal emptying and secretion in the preruminant calf. *J Physiol* 1982;322:409-417.
39. Mylrea PJ. Digestion of milk in young calves. I. Flow and acidity of the contents of the small intestine. *Res Vet Sci* 1966;7:333-341.
40. Mylrea PJ. Functioning of the digestive tract of young fasted calves. *Res Vet Sci* 1968;9:1-4.
41. Lohmann KL, Roussel AJ, Cohen ND, et al. Comparison of nuclear scintigraphy and acetaminophen absorption as a means of studying gastric emptying in horses. *Am J Vet Res* 2000;61:310-315.