

Reference range values of regional left ventricular myocardial velocities and time intervals assessed by tissue Doppler imaging in young nonsedated Maine Coon cats

Valerie Chetboul, DVM, PhD; Carolina Carlos Sampedrano, DVM, MS; Renaud Tissier, DVM, PhD; Vassiliki Gouni, DVM; Audrey P. Nicolle, DVM; Jean-Louis Pouchelon, DVM, PhD

Objective—To describe and analyze the left ventricular free wall (LVFW) radial and longitudinal motions in a population of healthy Maine Coon cats by use of quantitative 2-dimensional color tissue Doppler imaging (TDI).

Animals—23 healthy young Maine Coon cats (mean \pm SD: age, 2.1 ± 0.9 years; weight, 5.0 ± 1.0 kg).

Procedure—TDI was performed by the same trained observer (VC) on all cats. Radial LVFW velocities were recorded in endocardial and epicardial LVFW segments, and longitudinal velocities were recorded in the mitral annulus and in basal and apical LVFW segments. Isovolumic contraction and relaxation times were calculated in each myocardial segment, and the coefficients of variation (CVs; %) were determined for each TDI parameter.

Results—LVFW velocities were significantly higher in the endocardial layers than in the epicardial layers and also significantly higher in the basal than in the apical segments. Annular velocities were significantly higher than basal myocardial velocities in systole and early diastole. Coefficient of variation values were lower for radial velocities, particularly in systole, and were also lower for time intervals (16% to 22%) than for myocardial velocities (19% to 62%).

Conclusions and Clinical Relevance—Because Maine Coon cats are predisposed to an inherited hypertrophic cardiomyopathy, which is a common cause of death in this breed, TDI could provide a useful tool for early detection of the disease. Tissue Doppler imaging indices may complete the conventional analysis of the left ventricular function in Maine Coon cats. However, the usefulness of TDI indices in the early detection of myocardial dysfunction needs to be clarified. (*Am J Vet Res* 2005;66:1936–1942)

Hypertrophic cardiomyopathy is a common hereditary disease in humans and is present in about 2 out of 1,000 young adults¹; for more than 30 years, it has been recognized as a frequent cause of congestive heart failure, sudden death, and arterial thromboembolism in cats.^{2,3} A naturally occurring form of hypertrophic cardiomyopathy that closely mimics the

human disease has been described in Maine Coon cats.⁶ In this species, the myocardial disease seems to be inherited as an autosomal dominant trait with penetrance that increases to 100% in adulthood.⁶ It is characterized by moderate to severe left ventricular concentric hypertrophy and the typical histopathologic features seen in human hypertrophic cardiomyopathy.

Conventional ultrasound techniques have considerably enhanced the diagnosis of myocardial diseases in veterinary medicine, permitting measurements of atrial and ventricular size, myocardial thickness, and systolic function. **Tissue Doppler imaging (TDI)** is a more recent ultrasound method for analyzing global and segmental myocardial function in small animals.⁷ Tissue Doppler imaging offers a new, sensitive, noninvasive, and quantitative *in vivo* analysis of the 2 intrinsic motions of the myocardium (ie, radial^{8,9} and longitudinal^{10,11}) that can be used for the early diagnosis of myocardial dysfunction.¹²

To determine the repeatability and reproducibility of TDI as a prerequisite for use, TDI was performed in awake cats as a means of assessing radial and longitudinal left ventricular free wall (LVFW) movements.¹³ Prospective TDI studies are now needed in healthy feline populations to establish the reference range values for the radial and longitudinal myocardial TDI indices. The purposes of the study reported here were to describe and analyze the LVFW radial and longitudinal motion in a population of healthy young Maine Coon cats by use of quantitative 2-dimensional color TDI and to determine the TDI reference range values for myocardial velocities, myocardial isovolumic relaxation, and contraction times (time intervals) in different LVFW segments.

Materials and Methods

Animals—The procedures used in this experiment were performed in accordance with the National Institute of Health *Guide for the care and use of laboratory animals* and approved by the Animal Use and Care Committee of the National Veterinary School of Alfort. The study was performed in the Cardiology Unit of the National Veterinary School of Alfort. Young healthy Maine Coon cats that were < 4 years old were used in the study. All cats were free of medication and had no history of heart or respiratory disease. The owner's consent was obtained for each cat before enrollment in the study. All cats were determined to be healthy on the basis of findings on complete physical examinations, systemic arterial blood pressure measurements, ECGs, and plasma biochemical analyses (ie, determination of glucose, urea, and creatinine concentrations). Cats with hyperglycemia (reference

Received December 30, 2004.

Accepted March 8, 2005.

From the Unité de Cardiologie d'Alfort, Ecole Nationale Vétérinaire d'Alfort, 7 avenue du Général de Gaulle, 94704 Maisons-Alfort cedex, France (Chetboul, Carlos Sampedrano, Tissier, Gouni, Nicolle, Pouchelon); and the INSERM U660, 94704 Maisons-Alfort cedex, France (Chetboul, Tissier, Pouchelon).

Address correspondence to Dr. Chetboul.

interval, 80 to 120 mg/dL), high plasma urea concentration (reference interval, 0.15 to 0.56 g/L), or high plasma creatinine concentration (reference interval, 0.5 to 1.5 mg/dL) as well as cats with systemic hypertension (systolic arterial pressure > 160 mm Hg in unstressed cats^a) were excluded from the study. Systolic arterial blood pressure was measured indirectly in awake cats by the same trained observer (CCS) using the Doppler method.^b A period of acclimatization was allowed for each patient before measuring blood pressure. The owner held the cats gently in sternal or lateral recumbency. The hair under the tail was clipped over the first 5 proximal 5 cm. Several measurements were taken over 5 to 10 minutes to obtain the average of 5 values from a stable set of measurements. Standard echocardiographic and Doppler examinations were also performed just before the study to confirm normal heart anatomy and function.

Conventional echocardiography and Doppler examination—Standard transthoracic echocardiography with continuous ECG monitoring was performed by the same trained observer (VC) by use of an ultrasound unit^c equipped with a 7.5- to 10-MHz phased-array transducer. All of the conventional ultrasound examinations were performed in awake cats that were gently restrained in the standing position, as this method had already been validated in our cardiology unit.¹⁴ A mean of 3 measurements was obtained for each parameter on 3 consecutive cardiac cycles on the same frame. Ventricular measurements were taken from the right parasternal location (short-axis view) by use of the 2-dimensional-guided M-mode,¹⁵ according to the recommendations of the American Society of Echocardiography.¹⁶ Left ventricular end-diastolic and end-systolic diameters, LVFW thickness, and interventricular septal thickness in diastole and in systole were measured. The left ventricular **fractional shortening percent** (%FS) was then calculated. Measurements of the aortic and the left atrial diameter were obtained by use of a 2-dimensional method¹⁷ involving a short-axis, right-sided parasternal view obtained at the level of the aortic valve, where the commissures of the cusps could be observed during diastole. The internal short-axis diameter of the aorta was measured along the commissure between the noncoronary and left coronary aortic valve cusps. The left atrial diameter was measured by use of the same frame in a line extending from and parallel to the commissure between the noncoronary and left coronary aortic valve cusps. The left atrial-to-aortic ratio was then calculated. Finally, the maximal systolic aortic and diastolic mitral velocities were determined by use of pulsed-wave Doppler imaging. Aortic systolic flow velocities were recorded by use of the left apical 5-chamber view, and mitral diastolic velocities (ie, early and late diastole velocities) were obtained from the left apical 4-chamber view.

Color TDI—The 2-dimensional color TDI was performed in awake standing cats with continuous ECG monitoring by the same trained observer (VC) and by using of the same ultrasound unit^c as for standard echocardiography. Observer performance, in terms of repeatability and reproducibility, had already been documented in awake cats.¹⁵ In each examination, the gray-scale receive gain was set to optimize the clarity of the LVFW endocardial and epicardial boundaries. Off-line measurements of segmental myocardial velocities were obtained from color Doppler images of the LVFW. Real-time color Doppler was superimposed on the gray scale with a frame rate of ≥ 100 frames/s. The Doppler receive gain was adjusted to maintain optimal coloring of the myocardium, and the Doppler velocity range was set as low as possible to avoid aliasing. Digital images were obtained, stored, and reviewed later by use of a stand-alone, off-line measuring system.^d A 2×2 -mm sample was used, and a tissue velocity profile was displayed in each sample location.

Three measurements of each myocardial velocity were taken on 3 consecutive cardiac cycles on the same frame, and the mean value was used for the analysis. The mean heart rate was calculated by ECG monitoring during each radial and longitudinal TDI from the same 3 cardiac cycles used for the velocity measurements.

Quantification of radial left ventricular velocities—The LVFW velocities resulting from the radial left ventricular motion were measured by use of the right parasternal ventricular short-axis view between the 2 papillary muscles, as previously described.¹³ Measurements were made in endocardial and epicardial segments of the LVFW. Simultaneous endocardial and epicardial velocity profiles were obtained during the off-line analysis. Radial myocardial velocities were determined in systole and early and late diastole. **Radial myocardial velocity gradients** (MVGs; cm/s), defined as the difference between endocardial and epicardial velocities, were calculated for each phase of the cardiac cycle.¹⁸

Quantification of longitudinal left ventricular velocities—The LVFW velocities resulting from the longitudinal left ventricular motion were measured by use of the standard left apical 4-chamber view, as previously described.¹³ Measurements were made in 3 segments: the mitral annulus and 2 myocardial segments in the internal midportions of the LVFW (ie, basal and apical segments). Simultaneous annular, basal, and apical velocity profiles were obtained during off-line analysis. Longitudinal annular and myocardial velocities were determined in systole and early and late diastole. Longitudinal MVGs (cm/s), defined as the difference between basal and apical velocities, were then calculated for each phase of the cardiac cycle.¹⁸

Statistical analysis—Data are expressed as mean \pm SD. The reference range was evaluated for echocardiographic and TDI parameters from the mean ± 2 SD. A Student paired *t* test was used to compare the endocardial and epicardial velocities at each phase of the cardiac cycle. The annular, basal, and apical velocities were compared by use of an ANOVA, followed if necessary by a post hoc Student *t* test with Bonferroni correction. Early and late diastolic velocities in each segment were compared by use of a paired Student *t* test. Pearson correlation coefficients were assessed between heart rate, body weight, or %FS and several conventional as well as TDI echocardiographic parameters. Values of *P* < 0.05 were considered significant.

Results

Animals—The study population consisted of 23 healthy young Maine Coon cats. The study included 5 sexually intact males and 18 sexually intact females (Table 1).

Standard echocardiographic and Doppler data—A significant positive correlation (*r* = 0.45) was

Table 1—Age; weight; heart rate; systolic blood pressure; and plasma glucose, urea, and creatinine concentrations in 23 healthy Maine Coon cats.

Variables	Mean \pm SD (range)
Age (y)	2.1 \pm 0.9 (0.9–4.0)
Body weight (kg)	5.0 \pm 1.0 (3.5–7.1)
Heart rate (beats/min)*	176 \pm 17 (140–200)
Systolic blood pressure (mm Hg)	140 \pm 13 (120–160)
Urea (g/L)	0.45 \pm 0.09 (0.25–0.55)
Creatinine (mg/L)	9.6 \pm 3.1 (5–15)
Glucose (g/L)	1.0 \pm 0.1 (0.8–1.2)

*Assessed by ECG.

observed between interventricular septal thickness in diastole and body weight (Tables 2 and 3). A similar but nonsignificant correlation ($r = 0.32$) was also observed with the LVFW in diastole. Coefficient of variation (CV) values for the conventional echocardiographic and Doppler parameters were between 11% and 19% and between 13% and 28%, respectively. Fusion of the 2 diastolic mitral waves (ie, early and late mitral waves) into 1 positive diastolic wave was observed for 6 of the 23 cats.

LVFW and mitral annular motion during TDI—All velocity profiles included 1 positive systolic wave (S wave) and 2 negative diastolic waves, an early diastolic wave (E wave) and a late diastolic wave (A wave; Figure 1). They also included 2 isovolumic

phases, the isovolumic contraction phase (from the end of the negative A wave to the beginning of the positive S wave) and the isovolumic relaxation phase (from the end of the positive S wave to the beginning of the negative E wave). Fusion of the 2 negative diastolic waves (E and A waves) into a single negative diastolic wave was observed in 4 of the 23 TDI radial and longitudinal examinations. The observed maximal heart rate permitting identification of the E and A waves was 197 and 194 beats/min for the radial and longitudinal motions, respectively.

Left ventricular radial motion during TDI—Myocardial velocities (Table 4) were significantly higher in the endocardial than in the epicardial segments in systole and in early and late diastole, thus

Table 2—Mean \pm SD values and coefficients of variation (CVs) obtained by conventional echocardiographic and Doppler techniques in 23 healthy Maine Coon cats.

Variables	Values for healthy Maine Coon cats			
	Mean \pm SD (Min – Max)	CV (%)	Reference range values*	Correlation between echocardiographic parameters and body weight (r value)
Morphologic parameters (n = 23)				
Left atrial to aortic ratio†	1.0 \pm 0.2 (0.8–1.8)	19	0.6–1.4	0.00 (NS)
Left ventricular diastolic diameter (mm)	16.9 \pm 1.8 (13.3–20.8)	11	13.3–20.6	–0.13 (NS)
Left ventricular systolic diameter (mm)	9.1 \pm 1.5 (6.5–12.7)	17	6.0–12.1	–0.07 (NS)
Left ventricular diastolic free wall (mm)	4.6 \pm 0.6 (3.5–5.6)	12	3.5–5.7	0.32 (NS)
Left ventricular systolic free wall (mm)	7.4 \pm 1.3 (4.2–9.5)	17	4.9–10.0	0.29 (NS)
Interventricular diastolic septum (mm)	4.7 \pm 0.7 (3.1–6.0)	15	3.3–6.1	0.45‡
Interventricular systolic septum (mm)	7.7 \pm 1.3 (6.0–12.1)	17	5.0–10.4	0.11 (NS)
Systolic functional parameters (n = 23)				
Fractional shortening (%)	47 \pm 6 (36–59)	12	36–59	–0.21 (NS)
Systolic aortic maximal velocity (m/s)§	1.1 \pm 0.2 (0.8–1.6)	17	0.7–1.5	NA
Diastolic Doppler parameters with distinct early and late mitral waves (n = 17)§				
Early mitral wave (m/s)	0.7 \pm 0.1 (0.5–1.0)	16	0.5–1.0	NA
Late mitral wave (m/s)	0.5 \pm 0.1 (0.3–0.8)	28	0.2–0.8	NA
Diastolic Doppler parameters with merged early and late mitral waves (n = 6)§				
Merged mitral waves (m/s)	0.80 \pm 0.10 (0.7–0.9)	NC	NC	NA
Time parameters§				
Isovolumic relaxation time (ms)	53 \pm 10 (38–76)	19	33–73	NA
Early deceleration time (ms)	56 \pm 7 (46–68)	13	41–71	NA

*Reference range values are considered as mean \pm 2 SD. †Assessed by use of the 2-dimensional mode. ‡Significant ($P < 0.05$) correlation. §Assessed by pulsed wave Doppler. Min = Minimum value. Max = Maximum value. NS = Not a significant correlation. NC = Not calculated because of the low number of cats. NA = Not applicable.

Table 3—Published^{19,20} mean \pm SD values obtained by conventional echocardiographic and Doppler techniques in feline breeds other than Maine Coon cats.

Variables	Mean \pm SD (Min – Max) values	
	Other feline breeds	Other feline breed with hypertrophic cardiomyopathy**
Morphologic parameters		
Left atrial to aortic ratio#	1.30 \pm 0.17(0.95–1.65)†	NA
Left ventricular diastolic diameter (mm)	14.6 \pm 2.0 (10.7–20.7)*	14.4 \pm 1.9 (10.1–18.3)
Left ventricular systolic diameter (mm)	8.2 \pm 1.5 (4.9–11.6)*	6.9 \pm 1.5 (3.5–10.3)
Left ventricular diastolic free wall (mm)	3.6 \pm 0.6 (2.1–4.6)*	6.8 \pm 1.6 (3.9–11.4)
Left ventricular systolic free wall (mm)	6.8 \pm 0.7 (5.4–8.1)†	NA
Interventricular diastolic septum (mm)	3.7 \pm 0.7 (2.2–4.9)*	6.5 \pm 1.4 (3.4–12.3)
Interventricular systolic septum (mm)	5.8 \pm 0.6 (4.7–7.0)†	NA
Systolic functional parameter		
Fractional shortening (%)	44.2 \pm 8.2 (30–60)*	51.5 \pm 8.9 (36–73)

*Data from study by Fox et al¹⁹ on 37 healthy domestic shorthair cats. **Data from study by Fox et al¹⁹ on 46 cats with hypertrophic cardiomyopathy. †Data from study by Jabobs et al²⁰ on 30 healthy cats of 4 breeds (mostly domestic shorthair cats). #Assessed by use of the M-mode. NA = Not available.

defining a substantial intramyocardial gradient between the inner and outer layers of the LVFW as follows: mean \pm SD radial MVGs were 2.5 ± 0.8 cm/s (range, 1.0 to 4.3 cm/s), 3.3 ± 1.3 cm/s (range, 1.3 to 6.2 cm/s), and 1.7 ± 0.9 cm/s (range, 0.2 to 2.9 cm/s) in systole, early diastole, and late diastole, respectively. The highest radial velocities were recorded in the endocardial layers in early diastole, with the velocity recorded from the E wave significantly greater than that recorded from the A wave. In the epicardial layers, the velocity recorded from the E wave was also significantly greater than that recorded from the A wave. The CV values for the radial myocardial velocities were between 19% and 48%, whereas those of isovolumic contraction and relaxation times were between 16% and 22%. No correlation was found between body weight or heart rate and any radial TDI parameter (ie, myocardial velocities and time intervals). A significant ($r = 0.44$; $P = 0.034$) correlation was observed between %FS and systolic endocardial velocities but not between %FS and systolic epicardial velocities ($r = 0.05$; $P = 0.820$).

Left ventricular longitudinal motion during TDI—Myocardial velocities (recorded from the S, E, and A waves; Table 5) were significantly higher in the basal than in the apical segments, thus defining a substantial intramyocardial gradient along the LVFW from the base to the apex (Figure 1) as follows: mean \pm SD longitudinal MVGs were 2.9 ± 0.9 cm/s (range, 1.3 to 5.5 cm/s), 3.4 ± 1.5 cm/s (range, 1.0 to 6.4 cm/s), and 2.3 ± 0.9 cm/s (range, 0.5 to 4.4 cm/s) in systole, early diastole, and late diastole, respectively. Mitral valve annular velocities were also significantly higher than

basal velocities in systole and early diastole. The highest longitudinal velocities were recorded in the annular segment in early diastole, with the velocity recorded from the E wave significantly greater than that record-

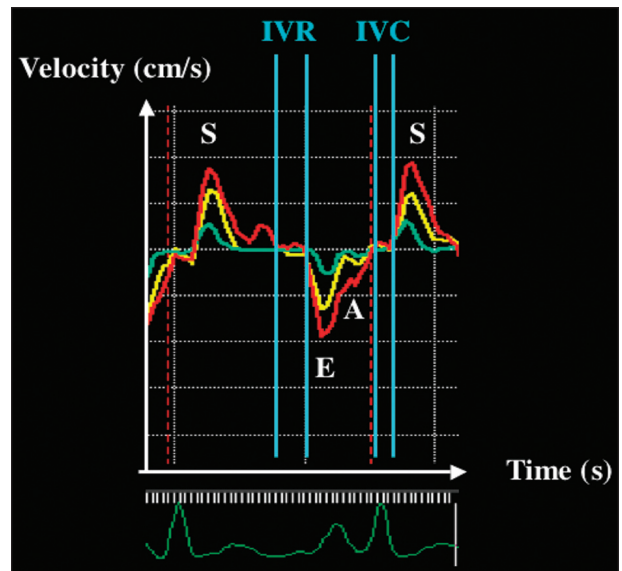


Figure 1—Longitudinal velocity profiles obtained from the left apical 4-chamber view in a Maine Coon cat. The simultaneous recording of the velocities in the mitral valve annulus (red curve) and 2 myocardial segments of the left ventricular free wall (LVFW; basal and apical, respectively, yellow and green curves) reveals that the mitral annulus is moving more rapidly than the basal segment and that the basal segment is moving more rapidly than the apical segment in systole and also in diastole. S, E, and A = Peak mean velocity of the LVFW during systole, early diastole, and late diastole, respectively. IVC = Isovolumic contraction time. IVR = Isovolumic relaxation time.

Table 4—Mean \pm SD values and CV of radial motion tissue Doppler imaging (TDI) parameters in 23 healthy Maine Coon cats.

Variables	Values for healthy Maine Coon cats				
	Mean \pm SD (Min – Max)	CV (%)	Reference range values*	Correlation between TDI parameters and body weight (r value)	Correlation between TDI parameters and heart rate (r value)
Systolic radial velocities (n = 23)					
S wave in endocardium (cm/s)	5.2 \pm 1.0 (3.6–7.0)	19	3.2–7.2	–0.09 (NS)	0.02 (NS)
S wave in epicardium (cm/s)	2.7 \pm 0.8 (1.8–4.8)†	28	1.2–4.2	0.00 (NS)	–0.06 (NS)
Diastolic radial velocities with distinct E and A waves (n = 19)					
E wave in endocardium (cm/s)	5.9 \pm 1.9 (2.3–10.4)	33	2.0–9.8	–0.04 (NS)	0.00 (NS)
E wave in epicardium (cm/s)	2.6 \pm 1.2 (0.5–5.6)†	48	0.1–5.0	0.15 (NS)	0.02 (NS)
A wave in endocardium (cm/s)	3.2 \pm 1.1 (1.3–5.0)§	35	1.0–5.4	–0.04 (NS)	0.00 (NS)
A wave in epicardium (cm/s)	1.5 \pm 0.7 (0.4–3.2)†‡	48	0.1–3.0	0.02 (NS)	0.2 (NS)
Diastolic radial velocities with merged E and A waves (n = 4)					
Merged EA wave in endocardium (cm/s)	5.6 \pm 0.3 (5.4–6.0)	NC	NC	NC	NC
Merged EA wave in epicardium (cm/s)	2.4 \pm 0.9 (1.9–3.8)†	NC	NC	NC	NC
Time parameters (n = 23)					
Isovolumic contraction time measured in the endocardium (ms)	36 \pm 8 (24–51)	22	20–51	–0.08 (NS)	0.15 (NS)
Isovolumic contraction time measured in the epicardium (ms)	36 \pm 7 (24–51)	20	22–50	–0.13 (NS)	0.16 (NS)
Isovolumic relaxation time measured in the endocardium (ms)	45 \pm 7 (35–63)	16	31–60	0.17 (NS)	–0.26 (NS)
Isovolumic relaxation time measured in the epicardium (ms)	45 \pm 7 (35–63)	16	31–60	0.13 (NS)	–0.30 (NS)
Heart rate (beats/min)	179 \pm 18 (148–214)	10	NA	NA	NA

*Reference range values are considered as mean \pm 2 SD. †Significantly ($P < 0.001$) different than corresponding endocardial value. ‡Significantly ($P < 0.01$) different than corresponding early diastolic value. §Significantly ($P < 0.001$) different than corresponding early diastolic value. E wave = Early diastolic wave. A wave = Late diastolic wave. See Tables 2 and 3 for remainder of key.

Table 5—Mean ± SD and CVs of longitudinal motion TDI parameters in 23 healthy Maine Coon cats.

Variables	Values for healthy Maine Coon cats				
	Mean ± SD (Min – Max)	CV (%)	Reference range values*	Correlation between TDI parameters and body weight (<i>r</i> value)	Correlation between TDI parameters and heart rate (<i>r</i> value)
Systolic longitudinal velocities (n = 23)					
S wave at the mitral valve annulus (cm/s)	5.4 ± 1.3 (3.4–8.4)	23	2.9–8.0	0.15 (NS)	–0.07 (NS)
S wave in the basal segment (cm/s)	4.7 ± 1.4 (2.4–7.9)	29	1.9–7.5	0.18 (NS)	–0.02 (NS)
S wave in the apical segment (cm/s)	1.8 ± 1.1 (0.2–4.2)‡	62	0.0–3.9	0.20 (NS)	–0.04 (NS)
Diastolic longitudinal velocities with distinct E and A waves (n = 19)					
E wave at the mitral valve annulus (cm/s)	6.0 ± 1.4 (4.0–9.9)	24	3.1–8.8	0.06 (NS)	0.38#
E wave in the basal segment (cm/s)	5.7 ± 1.7 (3.3–9.9)§	31	2.2–9.2	0.00 (NS)	0.22 (NS)
E wave in the apical segment (cm/s)	2.3 ± 1.0 (0.5–3.9)‡	43	0.3–4.3	0.03 (NS)	0.16 (NS)
A wave at the mitral valve annulus (cm/s)	3.4 ± 1.0 (1.8–5.2)	29	1.5 ± 5.4	–0.28 (NS)	0.34 (NS)
A wave in the basal segment (cm/s)	3.3 ± 1.1 (1.7–5.4)	32	1.2 ± 5.4	–0.18 (NS)	0.23 (NS)
A wave in the apical segment (cm/s)	1.1 ± 0.6 (0.4–2.1)‡ ¶	52	0.0–2.2	–0.09 (NS)	0.25 (NS)
Diastolic longitudinal velocities with merged E and A waves (n = 4)					
Merged EA wave at the mitral valve annulus (cm/s)	7.5 ± 3.1 (4.2–11.6)	NC	NC	NC	NC
Merged EA wave in the basal segment (cm/s)	7.2 ± 3.1 (5.1–11.7)	NC	NC	NC	NC
Merged EA wave in the apical segment (cm/s)	2.4 ± 1.4 (0.5–3.5)†§	NC	NC	NC	NC
Time parameters (n = 23)					
Isovolumic contraction time measured in the basal segment (ms)	34 ± 7 (23–49)	21	20–48	–0.29 (NS)	–0.32 (NS)
Isovolumic contraction time measured in the apical segment (ms)	34 ± 7 (23–49)	21	20–48	–0.29 (NS)	–0.32 (NS)
Isovolumic relaxation time measured in the basal segment (ms)	51 ± 9 (36–65)	17	33–68	0.15 (NS)	–0.29 (NS)
Isovolumic relaxation time measured in the apical segment (ms)	51 ± 9 (36–65)	17	33–68	0.15 (NS)	–0.29 (NS)
Heart rate (beats/min)	179 ± 28 (148–250)	16	NA	NA	NA

†Significantly (*P* < 0.05) different than corresponding basal value. ‡Significantly (*P* < 0.001) different than corresponding basal value.
§Significantly (*P* < 0.05) different than corresponding mitral valve annular value. ||Significantly (*P* < 0.001) different than corresponding mitral
valve annular value. ¶Significantly (*P* < 0.001) different than corresponding early diastolic value. #Significant (*P* < 0.05) correlation.
See Tables 2 and 4 for remainder of key.

ed from the A wave. In the myocardial segments (ie, basal and apical), the velocity recorded from the E wave was also significantly greater than that recorded from the A wave. The CV values for the longitudinal myocardial velocities were between 23% and 62%, whereas those of isovolumic contraction and relaxation times were between 17% and 21%. No correlation was found between body weight and any longitudinal TDI parameter. No significant correlation was found between heart rate and any longitudinal TDI parameter, except for early diastolic mitral valve annular velocities (*r* = 0.38). A significant correlation was observed between %FS and systolic longitudinal basal (*r* = 0.39; *P* = 0.047) and apical (*r* = 0.57; *P* = 0.005) myocardial velocities but not between %FS and systolic annular velocities (*r* = 0.35; *P* = 0.136).

Discussion

To our knowledge, our study is the first to provide accurate information on the velocity patterns of short-axis and long-axis LVFW motion as well as longitudinal mitral valve annular motion obtained by 2-dimensional color TDI in healthy Maine Coon cats. The mitral annular velocities provide information on global left ventricular function, whereas analysis of the motion in different myocardial segments gives an indication of regional longitudinal and radial myocardial function. The 2 analyses are therefore complementary.

Two views were needed to analyze the radial and longitudinal (myocardial or annular) velocities (ie, the right parasternal ventricular short-axis view and the left apical 4-chamber view).

We have already reported the breed dependency of several TDI variables in dogs as follows²¹: the mean longitudinal myocardial S waves in Belgian Malinois, for example, are 1.5- to 3.1-fold higher than those of Beagles. This led us, in our current study, to define specific TDI reference intervals for the Maine Coon cat, which is of particular interest in TDI because of the breed's predisposition to a familial form of hypertrophic cardiomyopathy. Healthy young Maine Coon cats (≤ 4 years old) were deliberately chosen for our study, as this cardiomyopathy usually affects young Maine Coon cats with a nadir between 1.5 and 3 years of age; however, in a few cats, the disease may not be apparent until 3 to 4 years of age.⁶

One particularity of the hypertrophic cardiomyopathy in Maine Coon cats is that the myocardial thickening is more commonly confined to, or more severe in, the LVFW than in the interventricular septum.⁶ Reference range values for the LVFW velocities in this species could therefore be useful, particularly in the early and accurate diagnosis of this feline disease in the following situations: in Maine Coon cats with equivocal conventional echocardiographic findings (similar to that reported²² for dogs with spontaneous dilated

cardiomyopathy) and in Maine Coon cats that lack evident LVFW dysfunction but that have parents known to have been affected by cardiomyopathy (as found for dogs that have Golden Retriever muscular dystrophy^{23,12}). To our knowledge, the success of TDI in early detection of hypertrophic cardiomyopathy has never been studied in cats but has already been shown in human patients²⁴ and in a model of hypertrophic cardiomyopathy in transgenic rabbits.²⁵ In the latter study,²⁵ systolic and diastolic TDI alterations were detected in all affected rabbits, even those without left ventricular hypertrophy, irrespective of the extent of cardiac hypertrophy.

In our study, all of the radial and longitudinal velocity profiles included, after a short isovolumic contraction phase, 1 positive S wave and, after a short isovolumic relaxation phase, 2 diastolic negative waves (ie, E and A waves). Similar velocity profiles have also been described in healthy awake dogs.²¹ In our study, a fusion of the 2 negative diastolic waves into a single negative diastolic wave was observed in 4 of the 23 TDI radial and longitudinal examinations. This fusion of the 2 negative diastolic waves as a result of a high heart rate was observed when the heart rate was between 192 and 250 beats/min. This E wave and A wave summation was not observed in any of the 100 dogs in the canine study,²¹ probably as a result of the lower heart rate (103 ± 24 beats/min and 97 ± 23 beats/min during the radial and longitudinal TDI examinations, respectively).

As expected and already found in dogs,^{21,26} our data indicate that the LVFW segments move with different velocities. The endocardial layers in systole and diastole move significantly more rapidly than the epicardial layers, thereby producing an intramyocardial radial velocity gradient. In addition, the LVFW velocities decrease significantly from the base toward the apex, producing another MVG, the intramyocardial longitudinal velocity gradient. These gradients are more sensitive TDI parameters than the isolated velocity values in humans^{27,28} and dogs.¹²

All of the radial and longitudinal velocity profiles in our study were parallel. Moreover, no significant differences were observed in the isovolumic times between the endocardial and epicardial segments or between the basal and apical segments, which had similar ranges and CV values. These results suggest a sort of synchronism of motion between the myocardial segments, although other TDI parameters, such as time-to-peak velocity or delay between the onset of the QRS complex and the onset of the systolic TDI wave, would need to be studied in many more myocardial segments to perfectly document intraventricular myocardial synchrony.

The CV values of the isovolumic time indices were much lower than those obtained with myocardial velocities (ie, CV between 10% and 22% vs 19% and 62% for myocardial velocities). This suggests their potential interest as follow-up TDI parameters but will need to be confirmed in studies involving cats with disease.

The highest CV values (43% to 62%) were obtained in the myocardial apical segment. It has already been shown in healthy awake cats,¹³ dogs,²⁶ and humans¹¹ that the variability of LVFW velocities mea-

sured in the apical segments is much higher than in the basal segments. This may be due to less-than-optimal visualization of the apical endocardial surfaces and greater difficulty in orientation of the Doppler angle of incidence. This inability to produce reliable measurements of myocardial velocities in the apical segments may represent a limitation of the TDI technique. However, even if the apical myocardial velocities are variable, an analysis of the velocity patterns in these segments is of interest to confirm the good synchrony with the basal segment and also to check the presence of the 3 velocity waves, with E systematically $> A$.

Our results indicate that a positive correlation exists between the early diastolic mitral valve annular velocities and heart rate. However, no correlation between heart rate and other TDI parameters was observed. A similar positive correlation between heart rate and early diastolic myocardial velocities has already been found in the endocardial and basal segments of the healthy Chartreux cat.¹³ In this feline study,¹³ heart rate was also correlated with systolic velocities in the endocardial, epicardial, and basal segments.

In our study, a correlation was also found between most systolic myocardial velocities and %FS. This correlation, which was not observed in the population of 100 healthy dogs,²¹ has already been observed, albeit moderately, in healthy human patients.¹¹

Results of studies on TDI in healthy human subjects¹¹ and clinically normal cats²⁹ reveal that the left myocardial velocity patterns change with age, with a progressive decrease in systolic and early diastolic velocities associated with an increase in late diastolic velocities. This effect of age was not analyzed in our study, as the age range was relatively small (between 1 and 4 years old). Interestingly, an effect of body weight was not observed for any of the TDI variables, in contrast to standard echocardiographic parameters. The absence of a body weight effect on TDI velocities has been observed in 4 breeds of dog, Beagles, German Shepherd Dogs, Belgian Shepherd Dogs, and Golden Retrievers ($n = 66$).²¹

The major limit of our study is that interventricular septal velocities were not recorded in any of these healthy Maine Coon cats. The left ventricular synchrony between the interventricular septum and LVFW, therefore, could not be analyzed. Such data would have provided more information on the use of TDI to assess normal feline left ventricular function. The other limit involves the study patients. Hypertrophic cardiomyopathy is known to affect males more than females,⁶ and our study included 18 females but only 5 males. This gender imbalance may perhaps have affected the data, although no gender effect has been observed for any conventional or TDI variable in a population of 100 healthy dogs.²¹

In conclusion, results of our study provide reference range values for the velocities and time intervals of mitral valve annulus and LVFW in the Maine Coon cat by use of the 2-dimensional color TDI technique. Prospective studies involving Maine Coon cats affected by the familial form of hypertrophic cardiomyopathy are now required to determine the sensitivity, specific-

ty, and clinical relevance of these new myocardial and TDI annular indices.

- a. Stepien RL. Blood pressure measurement: equipment, methodology and clinical recommendations (abstr), in *Proceedings*. 22nd Am Coll Vet Intern Med Forum 2004;605–607.
- b. 811-BL, Parks Medical Electronics Inc, Aloha, Ore.
- c. General Electric medical system, General Electric Co, Waukesha, Wis.
- d. Echo Pac 5.4 software for Vivid 5, GE-Vingmed Ultrasound, Waukesha, Wis.

References

1. Maron BJ, Gardin JM, Flack JM, et al. Prevalence of hypertrophic cardiomyopathy in a general population of young adults. Echocardiographic analysis of 4111 subjects in the CARDIA Study. Coronary Artery Risk Development in (Young) Adults. *Circulation* 1995;92:785–789.
2. Tilley LP, Liu SK, Gilbertson SR, et al. Primary myocardial disease in the cat. A model for human cardiomyopathy. *Am J Pathol* 1977;86:493–522.
3. Tilley LP. Cardiomyopathy and thromboembolism in the cat. *Vet Med Small Anim Clin* 1975;70:313–316.
4. Batty CJ. Feline hypertrophic cardiomyopathy: an update. *Vet Clin North Am Small Anim Pract* 2004;34:1227–1234.
5. Ferasin L, Sturgess CP, Cannon MJ, et al. Feline idiopathic cardiomyopathy: a retrospective study of 106 cats (1994–2001). *J Feline Med Surg* 2003;5:151–159.
6. Kittleson MD, Meurs KM, Munro MJ, et al. Familial hypertrophic cardiomyopathy in Maine coon cats: an animal model of human disease. *Circulation* 1999;99:3172–3180.
7. Chetboul V. Tissue Doppler Imaging: a promising technique for quantifying regional myocardial function. *J Vet Cardiol* 2002;4:7–12.
8. Garcia-Fernandez MA, Zamorano J, Azevedo J. Normal patterns with Doppler tissue imaging. In: Garcia-Fernandez MA, Zamorano J, Azevedo J, eds. *Doppler tissue imaging echocardiography*. Madrid: McGraw-Hill Book Co, 1998;23–44.
9. Rychik J, Tian ZY. Quantitative assessment of myocardial tissue velocities in normal children with Doppler tissue imaging. *Am J Cardiol* 1996;77:1254–1257.
10. Haluska BA, Short L, Marwick TH. Relationship of ventricular longitudinal function to contractile reserve in patients with mitral regurgitation. *Am Heart J* 2003;146:183–188.
11. Nikitin NP, Witte KK, Thackray SD, et al. Longitudinal ventricular function: normal values of atrioventricular annular and myocardial velocities measured with quantitative two-dimensional color Doppler tissue imaging. *J Am Soc Echocardiogr* 2003;16:906–921.
12. Chetboul V, Escriou C, Tessier D, et al. Tissue Doppler imaging detects early asymptomatic myocardial abnormalities in a dog model of Duchenne's cardiomyopathy. *Eur Heart J* 2004;25:1934–1939.
13. Chetboul V, Athanassiadis N, Carlos C, et al. Quantification, repeatability, and reproducibility of feline radial and longitudinal left ventricular velocities by tissue Doppler imaging. *Am J Vet Res* 2004;65:566–572.
14. Chetboul V, Concordet D, Pouchelon JL, et al. Effects of inter- and intra-observer variability on echocardiographic measurements in awake cats. *J Vet Med A Physiol Pathol Clin Med* 2003;50:326–331.
15. Thomas WP, Gaber CE, Jacobs GJ, et al. Recommendations for standards in transthoracic two-dimensional echocardiography in the dog and cat. Echocardiography Committee of the Specialty of Cardiology, American College of Veterinary Internal Medicine. *J Vet Intern Med* 1993;7:247–252.
16. Sahn DJ, DeMaria A, Kisslo J, et al. Recommendations regarding quantitation in M-mode echocardiography: results of a survey of echocardiographic measurements. *Circulation* 1978;58:1072–1083.
17. Hansson K, Haggström J, Kvarn C, et al. Left atrial to aortic root indices using two-dimensional and M-mode echocardiography in Cavalier King Charles spaniels with and without left atrial enlargement. *Vet Radiol Ultrasound* 2002;43:568–575.
18. Uematsu M, Miyatake K, Tanaka N, et al. Myocardial velocity gradient as a new indicator of regional left ventricular contraction: detection by a two-dimensional tissue Doppler imaging technique. *J Am Coll Cardiol* 1995;26:217–223.
19. Fox PR, Liu SK, Maron BJ. Echocardiographic assessment of spontaneously occurring feline hypertrophic cardiomyopathy. An animal model of human disease. *Circulation* 1995;92:2645–2651.
20. Jacobs G, Knight DH. M-mode echocardiographic measurements in nonanesthetized healthy cats: effects of body weight, heart rate, and other variables. *Am J Vet Res* 1985;46:1705–1711.
21. Chetboul V, Carlos Sampedrano C, Concordet D, et al. Use of quantitative two-dimensional color tissue Doppler imaging for assessment of left ventricular radial and longitudinal myocardial velocities in dogs. *Am J Vet Res* 2005;66:953–961.
22. Chetboul V, Carlos Sampedrano C, Testault I, et al. Use of tissue Doppler imaging to confirm the diagnosis of dilated cardiomyopathy in a dog with equivocal echocardiographic findings. *J Am Vet Med Assoc* 2004;225:1877–1880.
23. Chetboul V, Carlos C, Blot S, et al. Tissue Doppler assessment of diastolic and systolic alterations of radial and longitudinal left ventricular motions in Golden Retrievers during the preclinical phase of cardiomyopathy associated with muscular dystrophy. *Am J Vet Res* 2004;65:1335–1341.
24. Nagueh SF, Bachinski LL, Meyer D, et al. Tissue Doppler imaging consistently detects myocardial abnormalities in patients with hypertrophic cardiomyopathy and provides a novel means for an early diagnosis before and independently of hypertrophy. *Circulation* 2001;104:128–130.
25. Nagueh SF, Kopelen HA, Lim DS, et al. Tissue Doppler imaging consistently detects myocardial contraction and relaxation abnormalities, irrespective of cardiac hypertrophy, in a transgenic rabbit model of human hypertrophic cardiomyopathy. *Circulation* 2000;102:1346–1350.
26. Chetboul V, Athanassiadis N, Carlos C, et al. Assessment of repeatability, reproducibility, and effect of anesthesia on determination of radial and longitudinal left ventricular velocities via tissue Doppler imaging in dogs. *Am J Vet Res* 2004;65:909–915.
27. Derumeaux G, Cochonnet O, Douillet R, et al. Comparison of myocardial velocities by tissue colour Doppler imaging in normal subjects and in dilated cardiomyopathy. *Arch Mal Coeur Vaiss* 1997;90:773–778.
28. Garot J, Derumeaux G, Monin JL, et al. Quantitative systolic and diastolic transmyocardial velocity gradients assessed by M-mode colour Doppler tissue imaging as reliable indicators of regional left ventricular function after acute myocardial infarction. *Eur Heart J* 1999;20:593–603.
29. Koffas H, Dukes-McEwan J, Corcoran BM, et al. Peak mean myocardial velocities and velocity gradients measured by color M-mode tissue Doppler imaging in healthy cats. *J Vet Intern Med* 2003;17:510–524.