

Evaluation of serum concentrations of biomarkers of skeletal metabolism and results of radiography as indicators of severity of osteochondrosis in foals

R. Clark Billinghamurst, DVM, PhD; Pieter A. J. Brama, DVM, PhD; P. Rene van Weeren, DVM, PhD; Megan S. Knowlton, BS; C. Wayne McIlwraith, BVSc, PhD

Objective—To determine whether serum concentrations of biomarkers of skeletal metabolism can, in conjunction with radiographic evaluation, indicate severity of osteochondrosis in developing horses.

Animals—43 Dutch Warmblood foals with varying severity of osteochondrosis.

Procedure—24 foals were monitored for 5 months and 19 foals were monitored for 11 months. Monthly radiographs of femoropatellar-femorotibial and tibiotarsal joints were graded for osteochondral abnormalities. Serial blood samples were assayed for 8 cartilage and bone biomarkers. At the end of the monitoring period, foals were examined for macroscopic osteochondrosis lesions.

Results—Temporal relationships were evident between certain serum biomarkers and osteochondrosis severity in foals during their first year. Biomarkers of collagen degradation (collagenase-generated neopeptides of type-II collagen fragments, type-I and -II collagen fragments [COL2-3/4C_{short}], and cross-linked telopeptide fragments of type-I collagen) and bone mineralization (osteocalcin) were positive indicators of osteochondrosis severity at 5 months of age. In foals with lesions at 11 months of age, osteochondrosis severity correlated negatively with COL2-3/4C_{short} and osteocalcin and positively with C-propeptide of type-II procollagen (CPII), a collagen synthesis marker. Radiographic grading of osteochondrosis lesions significantly correlated with macroscopic osteochondrosis severity score at both ages and was strongest when combined with osteocalcin at 5 months and CPII at 11 months.

Conclusions and Clinical Relevance—The ability of serum biomarkers to indicate osteochondrosis severity appears to depend on stage of disease and is strengthened with radiography. In older foals with more permanent lesions, osteochondrosis severity is significantly related to biomarker concentrations of decreased bone formation and increased cartilage synthesis. (*Am J Vet Res* 2004;65:143–150)

Bone formation in developing mammals is principally by a process known as endochondral ossification in which bone is formed in a scaffold of mineralized cartilage. Depending on the location of this process, endochondral ossification accounts for the formation of the supporting subchondral bone of joint surfaces (articular-epiphyseal cartilage complex), longitudinal growth of bones (metaphyseal growth plate), and production of secondary centers of ossification in cuboidal bones (carpal and tarsal bones). When there is abnormal bone and cartilage formation as a result of defects in endochondral ossification during mammalian development, lesions may develop in any or all of these locations.

Generalized metabolic disorders of endochondral ossification are known as dyschondroplasias and have been described in humans.¹ Osteochondrosis in domestic animals generally refers to localized defects in bone and cartilage, and it is a primary cause of osteoarthritis in domestic animals, especially pigs and horses.² In humans, the name of the disease varies depending on the affected site, but osteochondrosis dissecans in humans^{2,3} most closely resembles the condition seen in horses. The cause of osteochondrosis in horses is unknown, but putative factors include genetic predisposition, trauma, local ischemia, and endocrine dysfunction.⁴

Osteochondrosis is usually identified in its chronic stages when surgical treatment is often required to prevent further joint degeneration. There is an urgent need to identify individuals at earlier stages of the disease process because conservative methods of treatment can help affected animals resolve the condition when identified early.⁵ Moreover, because many of the initial lesions heal uneventfully,⁶ there is also a requirement for a method to differentiate potentially progressive defects from those likely to heal naturally. Radiography is the imaging modality currently used for detecting established lesions, and it can also be used to monitor disease progression; however, radiography is

Received June 6, 2003.

Accepted July 30, 2003.

From the Department of Clinical Sciences, College of Veterinary Medicine and Biomedical Sciences, Colorado State University, Fort Collins, CO 80523 (Billinghurst, Knowlton, McIlwraith); and the Department of Equine Sciences, Faculty of Veterinary Medicine, Utrecht University, Utrecht, The Netherlands (Brama, van Weeren). Dr. Billinghamurst's present address is the School of Health Sciences, St. Lawrence College, Kingston, ON, Canada K7L 5A6.

Supported by the Morris Animal Foundation.

Presented in part at the 48th Annual Meeting of the Orthopaedic Research Society, Dallas, February 2002.

The authors thank Drs. Albert Barneveld and Marianne Sloet as well as John Knapp for technical assistance.

Address correspondence Dr. Billinghamurst.

insensitive for detecting early changes, especially in cartilage.

Many investigators have attempted to identify molecules that can serve as early markers of metabolic abnormalities in specific tissues of the body. For the skeletal system, such biomarkers are continually being characterized for bone and cartilage. Alterations in the expression and distribution of components of the extracellular matrix of these tissues and the enzymes that degrade them have been reported⁷⁻¹² for osteochondrotic cartilage from horses. Of great interest to clinicians and researchers is the fact that concentrations of these biomarkers can be monitored through minimally invasive means in body fluids, such as blood, synovial fluid, and urine. Use of these techniques has been reported¹³⁻¹⁷ for horses with osteochondrosis.

In the longitudinal study reported here, we used radiographic and serum biomarker analyses to monitor, during the first year after birth, a population of young horses that were genetically predisposed to osteochondrosis. Our main hypothesis was that severity of osteochondrosis lesions, as defined on the basis of macroscopic tissue analyses, would be correlated with blood concentrations of specific biomarkers of cartilage or bone metabolism and could be identified early in the disease process. To this end, we assayed serially collected serum samples for a panel of collagen and noncollagenous protein molecules representative of specific metabolic activities in the skeletal tissues of developing mammals. Radiographs of commonly affected joints (ie, femoropatellar-femorotibial [ie, stifle] and tibiotarsal [ie, hock] joints) were obtained concurrently with the serum samples and scored for the severity of osteochondrosis lesions. Total macroscopic severity scores, as well as total counts of grossly identified osteochondrosis lesions, were used to identify the severity of osteochondrosis in each foal at 5 and 11 months of age.

Materials and Methods

Animals—Forty-three Dutch Warmblood foals (23 males and 20 females) that were all born in the same year and housed on the same stud farm in the Netherlands were used in the study. They were part of a large study¹⁸ designed to investigate the effect of exercise on osteochondrosis and musculoskeletal development in foals. All sires and 11 of 43 dams had radiographic evidence of osteochondrosis in the stifle or hock joints. The Utrecht University Ethical Committee approved all procedures involving the horses.

Procedure—Foals were kept in a paddock with the mares for the first week after birth and then allotted randomly to 3 groups (blocked on the basis of sex and sire) until weaning at 5 months of age. Foals in one group ($n = 14$) were confined to box stalls, foals in another group (14) were housed in box stalls but also given an increasing number of gallop sprints on 6 days of each week, and foals in a third group (15) were maintained on pasture. At 5 months of age, 8 foals from each group were randomly selected and euthanatized. Foals were sedated with detomidine and administered an overdose of barbiturate. The remaining 19 foals were maintained together in similar conditions (loose in a box stall with access to a paddock and no sprint training). These 19 foals were euthanatized when they reached 11 months of age; these foals were euthanatized as described previously. As reported elsewhere,¹⁹ osteochondrotic lesions were grossly

identified in all 24 foals euthanatized at 5 months of age and 17 of 19 foals euthanatized at 11 months of age, with most of the lesions evident in the hock joints for all ages of foals. We did not include a control group of unaffected foals in the study reported here.

Serum samples—Blood samples were collected from a jugular vein of all foals at 8 AM during the first week after birth and then at monthly intervals until foals were 5 months old; thereafter, samples were collected at 7, 9, and 11 months of age in the remaining 19 foals. Blood samples were collected into serum tubes and centrifuged at $500 \times g$ for 10 minutes; all samples were centrifuged within 30 minutes after collection. Sera were distributed into aliquots in cryotubes and frozen at -20°C within 90 minutes after collection. Serum samples were shipped frozen to the Orthopaedic Research Laboratory of Colorado State University, where the aliquots were stored at -80°C until assayed.

Radiographic examination—The stifle and hock joints of all foals were radiographed at monthly intervals, beginning at 1 month of age. Lateromedial and caudolateral-cranio-medial oblique views of both stifle joints and lateromedial, dorsoplantar, and dorsomedial-planterolateral oblique projections of both hock joints were always included for each foal. All radiographs from the study were independently graded by 2 investigators (PAJB and PRvW). Radiographs were graded on a scale of 0 to 4. The scale was based on bony contour (texture), subchondral bone density, and size of fragments, as described elsewhere.⁶ Grades were assigned as follows: 0, no abnormalities; 1, smoothly flattened bony contour or an obscure subchondral lucency; 2, irregularly flattened bony contour or a subchondral lucency with a poorly defined border; 3, small, rounded concavity or a subchondral lucency with a well-defined border or small fragments; and 4, large concavity with extensive subchondral lucency and large fragments. A radiographic osteochondrosis score was assigned, which represented the sum of the scores for each hock and stifle joint in each foal at each time point.

Evaluation of severity of osteochondrosis—Immediately after foals were euthanatized, all 26 major diarthrodial appendicular and axial joints in each foal were incised and inspected for macroscopic lesions. Macroscopic lesions were counted (lesion count) and scored for severity by use of a scale of 0 to 4, as described elsewhere.¹⁹ Scores were assigned as follows: 0, no abnormalities; 1, flattening of cartilage; 2, slightly irregular cartilage; 3, more severely irregular cartilage; and 4, classic osteochondrosis lesions with osteochondral fragments or cysts. Severity score for a joint was the sum of the scores for all lesions within that joint. The macroscopic osteochondrosis severity score reported and used for all analyses was the sum of the severity scores for each joint in each foal. All sites with macroscopically or radiographically suspected lesions were confirmed as osteochondrotic by histologic examination, as described elsewhere.¹⁹

Analysis of collagen biomarkers—The α chains of procollagen molecules initially are synthesized with extensions at the amino (N) and carboxyl (C) termini (ie, propeptides). During formation of extracellular fibrils, there is proteolytic removal of these propeptides from the triple-helical procollagen molecules, and these propeptides can be detected in tissues and body fluids as markers of collagen synthesis. The precision of each assay with equine sera was determined by calculating the intra- and inter-assay coefficient of variation (CV) for each assay. Linearity was confirmed by serial dilution of samples and comparison of observed values with expected values. Serum concentrations of the C-propeptide of type-I collagen (PICP) were estimated by use of a commercially available radioimmunoassay^a that has been validated for use in samples obtained from horses.²⁰ In the study reported here, equine sera were diluted 1:10 and the

intra- and interassay CV was < 6% and < 7%, respectively. Type-II collagen synthesis was determined by use of a newly available commercial ELISA.^b This assay used the same rabbit polyclonal IgG antiserum that is used in a radioimmunoassay for the C-propeptide of type-II procollagen (CPII), which has been validated for use in samples obtained from horses.^{16,21} In the study reported here, equine sera were diluted 1:2 and the intra- and interassay CV for CPII was < 4% and < 11%, respectively.

It is believed that the initiating factor in the degradation of collagen is cleavage of the triple-helical molecule into 3/4- and 1/4-length fragments by mammalian collagenases belonging to the matrix metalloproteinase (MMP) family (specifically, MMP-1, MMP-8, and MMP-13). The collagenase-generated termini of the individual cleaved fragments of the α chain are neoepitopes, and antibodies have been generated to detect these neoepitopes in tissues and fluids. We estimated type-II collagen degradation in the foals by use of an immunoassay designed to measure collagenase-generated neoepitope of type-II collagen fragments (234CEQ).²² This immunoassay was developed to react specifically with the collagenase-generated C-termini of the 3/4-length fragments of type-II collagen of horses. In the study reported here, equine sera were diluted 1:2 and the intra- and interassay CV for 234CEQ was < 4% and < 14%, respectively. An estimation of the cleavage of type-I and -II collagen by collagenases was made by use of an ELISA designed to measure collagenase-generated neoepitope of type-I and -II collagen fragments (COL2-3/4C_{short}).²³⁻²⁵ In the study reported here, equine sera were diluted 1:10 and the intra- and interassay CV for the COL2-3/4C_{short} assay was < 11% and < 33%, respectively.

We also evaluated turnover of type-I collagen by measuring serum concentrations of cross-linked degradation products by use of an ELISA^c performed in accordance with the manufacturer's instructions. This assay recognizes cross-linked telopeptide degradation fragment of type-I collagen (CTx1) released into the circulation when type-I collagen is degraded by osteoclasts during bone resorption. The ELISA has been validated for use in samples obtained from horses. In the study reported here, equine sera were assayed undiluted and the intra- and interassay CV for CTx1 was < 3% and < 9%, respectively.

Analysis of noncollagenous protein biomarkers—Two molecular markers that are indicative of anabolic processes in skeletal tissues are osteocalcin and the chondroitin sulfate 846 epitope (CS-846). Osteocalcin, also known as bone gla-protein, is the major noncollagenous protein of bone that is synthesized primarily by osteoblasts and hypertrophic chondrocytes, and it is believed to be associated with mineralization of newly formed osteoid.²⁶ A commercial ELISA^d that cross-reacts with equine osteocalcin²⁷ was used to estimate the osteocalcin concentration in serum samples; the ELISA was performed in accordance with the manufacturer's instructions. In the study reported here, equine sera were diluted 1:5 and the intra- and interassay CV for osteocalcin was < 4% and < 9%, respectively.

Aggrecan molecules are a main component of the extracellular matrix of articular cartilage and are responsible for the compressive strength of this tissue. Analysis of results of studies^{28,31} has suggested that aggrecan synthesis is reflected by the CS-846 that is found on some newly synthesized aggrecan molecules. A newly developed commercial ELISA for CS-846^e was used in the study reported here. This ELISA used the same mouse monoclonal IgM antibody that has been used in a radioimmunoassay for this epitope, as described elsewhere.³⁰ This antibody cross-reacts with equine aggrecan.^{16,21} In the study reported here, equine sera were diluted 1:5 and the intra- and interassay CV for CS-846 was < 7% and < 22%, respectively.

To serve as a general indicator of proteoglycan turnover, we measured serum concentrations of sulfated glycosamino-

glycans (sGAGs) by use of a dimethylmethylene blue colorimetric assay in papain-digested samples.³² In the study reported here, equine sera were diluted 1:2 and the intra- and interassay CV for sGAG concentrations was < 10% and < 11%, respectively.

Statistical analysis—Measurements obtained for most of the biomarkers evaluated in the study did not follow a normal distribution, as determined by use of the Kolmogorov-Smirnov test. Therefore, all serum biomarker values were logarithmically transformed (base 10), and all variables for severity of osteochondrosis (ie, macroscopic osteochondrosis severity score, lesion count, and radiographic score) were transformed to square roots. Normality of transformed data was confirmed, thereby allowing the use of more robust, parametric statistical tests.

Because we were evaluating concentrations of the biomarkers in serum, a fluid that contains metabolic products pooled from multiple sources throughout the body, further analyses were performed by use of total scores for macroscopic osteochondrosis severity and total number of osteochondrosis lesions. Multiple regression analysis was combined with backward step-wise elimination to identify those biomarkers, including radiographic scores, that best correlated with the severity of osteochondrosis changes identified in the foals during the first 11 months after birth. These regressions were performed as separate analyses for the 5- and 11-month-old groupings, given that there were differing exercise regimens during the first 5 months for all 43 foals and given that 24 of these horses were evaluated at 5 months for osteochondrosis lesions.

Significant correlations between the transformed variables for severity of osteochondrosis (macroscopic osteochondrosis severity score, lesion count, and radiographic score) and the transformed serum biomarker concentrations were determined by use of the Pearson correlation analysis. In addition, significant correlations were identified between osteochondrosis scores (at 5 and 11 months of age) and the monthly biomarker concentrations and radiographic scores. Multiple regression analysis with forward selection was performed to determine the combination of monthly measurements that best explained macroscopic osteochondrosis severity and total number of lesions in foals at both 5 and 11 months of age.

Statistical analyses were performed by use of commercially available software.^f Significance was determined at values of $P < 0.05$ for all tests.

Results

Osteochondrosis scores—All foals had osteochondrosis lesions at some point during the study; however, depending on the location of the lesions, 75% to 90% of the radiographically identified lesions at 1 month had resolved and were not apparent in radiographs taken at 11 months.⁶ It is important to mention that the various exercise regimens did not significantly affect the severity or number of osteochondrosis lesions in the foals at 5 months of age¹⁹ but did affect the serum concentrations of some of the biomarkers.³³ There was a significant reduction in the severity of osteochondrosis (as defined by histologic evaluation) in the stifle joints from 5 to 11 months of age but not in the hock joints during the same period.¹⁹ Because we did not have a group of unaffected horses, analyses of serum biomarker concentrations, radiographic scores, and their relationships to macroscopic osteochondrosis severity score and number of osteochondrosis lesions were performed in reference to the severity of osteochondrosis in foals during their first year after birth.

Severity of osteochondrosis at 5 months of age—Results of multiple regression analysis revealed that all biomarkers of collagen degradation (ie, COL2-3/4C_{short}, 234CEQ, and CTx1) were significantly and positively correlated (r^2 , 0.381; $P < 0.001$) with the severity of osteochondrosis determined by the total osteoarthroscopic severity scores and number of osteochondrosis lesions in the foals at 5 months of age. Monthly radiographic scores (hock plus stifle joints) were the best direct indicator of the variability in macroscopic osteochondrosis severity score and number of osteochondrosis lesions at 5 months of age ($P < 0.001$). Serum osteocalcin concentrations were also significantly and positively correlated with macroscopic osteochondrosis severity score and number of osteochondrosis lesions at 5 months of age. When analyzed on a monthly basis, radiographic scores and osteocalcin concentrations at 1 month of age had a significant relationship with the macroscopic osteochondrosis severity scores and total osteochondrosis lesion counts at 5 months of age (Fig 1 and 2). The only other biomarker that was significantly correlated with osteochondrosis severity, and in a negative manner, was serum sGAG concentrations.

Severity of osteochondrosis at 11 months of age—Monthly radiographic scores were significantly and positively correlated with the macroscopic osteochondrosis severity scores ($P < 0.001$) and lesion counts ($P = 0.007$) in foals evaluated at 11 months of age. Of mention is the fact that serum osteocalcin and COL2-3/4C_{short} concentrations were significantly correlated with macroscopic osteochondrosis severity scores and lesion counts; however, in contrast to the positive relationships at 5 months, they both had negative relationships at 11 months of age. The only other biomarker to contribute significantly to the model of osteochondrosis severity at 11 months of age was CII concentration, which was indicative of type-II collagen synthesis. It was significantly ($P < 0.001$) correlated with macroscopic osteochondrosis severity score and total lesion count. When analyzed on a monthly basis, the CII concentrations from 5 to 11 months of age accounted for 22% and 19% of the variability in the macroscopic osteochondrosis severity scores and osteochondrosis lesion count, respectively, for the 11-month-old foals (Fig 2). Results of radiographic examinations at 9 and 11 months of age were significantly correlated with macroscopic osteochondrosis

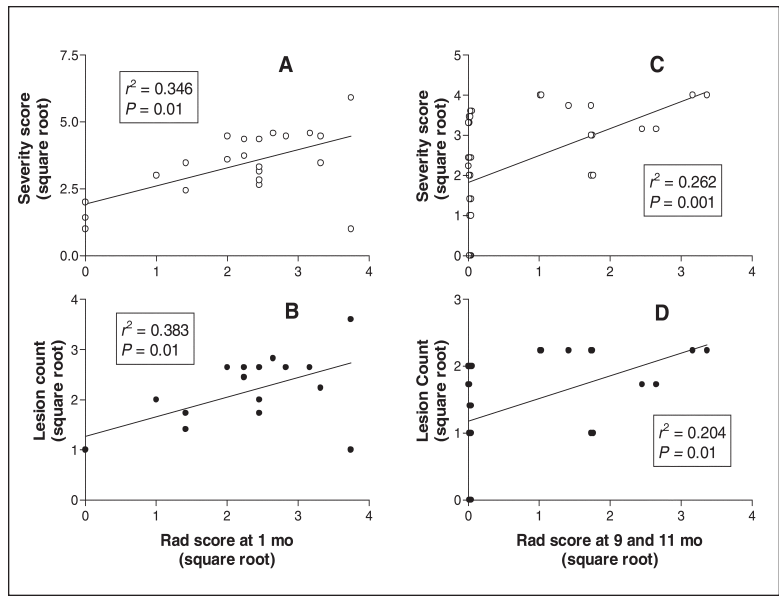


Figure 1—Correlations of total radiographic scores (Rad score) of the femoropatellar-femorotibial (ie, stifle) and tibiotarsal (ie, hock) joints with total macroscopic osteochondrosis severity scores (open circle) and total osteochondrosis lesion count (solid circle) in foals that were 5 months old (panels A and B) and 11 months old (panels C and D). Radiographic score for 1-month-old foals was plotted against total macroscopic osteochondrosis severity score (A) and total osteochondrosis lesion count (B) for the same 24 foals at 5 months of age. The Rad score at 9 and 11 months of age was plotted against total macroscopic osteochondrosis severity score (C) and total osteochondrosis lesion count (D) for the same 19 foals at 11 months. All scores were transformed (square root transformation) prior to analysis. Radiographic scores at these time points were significantly correlated with severity of osteochondrosis, as determined by use of Pearson correlation analyses. Linear regression analysis was used to determine the line of best fit for each plot.

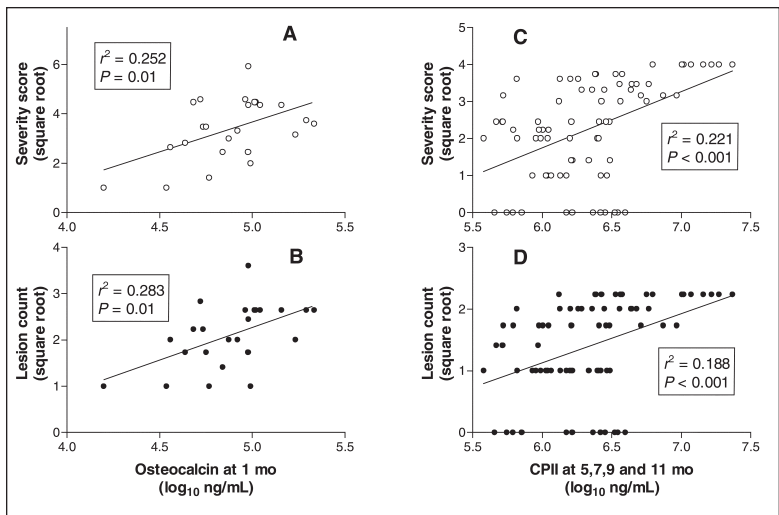


Figure 2—Correlations of serum biomarker concentrations with total macroscopic osteochondrosis severity scores (open circle) and total osteochondrosis lesion count (solid circle) in foals that were 5 months old (panels A and B) and 11 months old (panels C and D). Serum osteocalcin concentrations at 1 month of age were plotted against total macroscopic osteochondrosis severity score (A) and total osteochondrosis lesion count (B) for the same 24 foals at 5 months of age, and serum C-propeptide of type-II procollagen (CII) concentrations at 5, 7, 9, and 11 months of age were plotted against total macroscopic osteochondrosis severity score (C) and total osteochondrosis lesion count (D) for the same 19 foals at 11 months of age. Data were transformed (serum biomarker concentrations, log₁₀; macroscopic osteochondrosis severity scores and total osteochondrosis lesion counts, square root transformation) prior to analysis. Serum concentrations of osteocalcin and CII at these time points were significantly correlated with severity of osteochondrosis, as determined by use of Pearson correlation analyses. Linear regression analysis was used to determine the line of best fit for each plot.

severity scores and osteochondrosis lesion count at 11 months of age (Fig 1).

Correlations for serum biomarker concentrations and severity of osteochondrosis—Transformed serum biomarker concentrations for all foals were analyzed separately for correlations with the 3 methods used to score severity of osteochondrosis (ie, macroscopic osteochondrosis severity score, total osteochondrosis lesion count, and total [hock plus stifle joints] osteochondrosis radiographic scores). Results were similar to those for the regression analyses in that serum osteocalcin, COL2-3/4C_{short}, and CPII concentrations were significantly correlated with macroscopic osteochondrosis severity scores and lesion counts (Table 1). Total radiographic scores (hock plus stifle joints) were significantly correlated with concentrations of all serum biomarkers except sGAG concentrations. Total radiographic scores were also significantly ($P < 0.001$) and highly correlated with the macroscopic osteochondrosis severity scores (r , 0.4782) and lesion counts (r , 0.3844) within the hock and stifle joints only.

We attempted to determine whether macroscopic scoring and counting of lesions in only the hock and stifle joints would be adequate to assess osteochondrosis in these foals. We documented significant ($P < 0.001$) correlations between the total macroscopic osteochondrosis scores for the hock and stifle joints and total osteochondrosis lesion count (r , 0.7278) as well as between the total osteochondrosis lesion counts for the hock and stifle joints and total macroscopic osteochondrosis severity scores (r , 0.6494). Analysis of these results suggested that the osteochondrosis changes in the hock and stifle joints were representative of those throughout all joints in a foal and justify the use of radiography of only the hock and stifle joints for assessing severity of osteochondrosis in the entire horse.

Serum biomarker concentrations and age of foals—Relationships between serum concentrations of biomarkers and age of the foals have been reported elsewhere.³³ Briefly, serum concentrations of CTx1 and CPII increased significantly with age, whereas serum

concentrations of osteocalcin, CS-846, PICP, and sGAG decreased significantly with age. Serum concentrations of COL2-3/4C_{short} and 234CEQ did not change significantly with age in these foals.

Discussion

The ability to identify early stages of progressively debilitating orthopedic diseases before permanent and irreparable damage has developed is a goal of researchers investigating molecular markers of skeletal metabolism. We hypothesized that serial measurement of concentrations of a select group of biomarkers in body fluids, beginning at the time of birth in a population of horses genetically predisposed to developing a specific orthopedic condition (ie, osteochondrosis), would allow us to identify specific horses with more severe and potentially progressive lesions. This method would be combined with results of radiography, the diagnostic modality currently used to identify lesions in joints with a high predilection for osteochondrosis. In the study reported here, we documented that there were significant temporal differences in skeletal metabolism (as assessed by serum biomarker concentrations) and pathologic changes of joints (as determined by gross and radiographic examinations) in foals with osteochondrosis between the early (first 5 months) and late (subsequent 6 months) periods after birth.

Results of radiography were validated for use in assessing joints for the detection of osteochondrosis and determination of the severity of osteochondrosis in developing horses throughout the first year after birth. Furthermore, we documented that the radiographic assessment of joints with a high predilection for osteochondrosis (ie, hock and stifle joints³⁴) was representative of the number and severity of osteochondrosis lesions throughout the entire foal. Specifically, we determined that radiographs of the hock and stifle joints taken at 1 month of age were significantly correlated with severity and number of lesions at 5 months of age. However, because many lesions diagnosed radiographically at 1 month had resolved by 11 months and it has been reported³⁵ that new osteochondrosis

Table 1—Correlations between serum concentrations of biomarkers and 3 measures of osteochondrosis severity scores

Severity score	Osteocalcin	CPII	COL2-3/4 _{short}	234CEQ	CTx1	sGAGs	CS-846	PICP
Macroscopic								
r^2	0.165	0.212	0.137	-0.090	-0.105	0.005	0.105	0.112
P	0.003	< 0.001	0.015	NS	NS	NS	NS	NS
Lesion								
r^2	0.209	0.138	0.147	-0.066	-0.105	-0.011	0.140	0.159
P	< 0.001	0.014	0.009	NS	NS	NS	0.013	0.005
Radiographic								
r^2	0.208	0.180	0.243	-0.153	-0.144	0.024	0.305	0.208
P	< 0.001	0.003	< 0.001	0.012	0.018	NS	< 0.001	< 0.001

CPII = C-propeptide of type-II procollagen. COL2-3/4C_{short} = Collagenase-generated neopeptide of type-I and -II collagen fragments. 234CEQ = Collagenase-generated neopeptide of type-II collagen fragments. CTx1 = Cross-linked telopeptide degradation fragment of type-I collagen. sGAGs = Sulfated glycosaminoglycans. CS-846 = Chondroitin sulfate 846 epitope. PICP = C-propeptide of type-I collagen. Macroscopic = Macroscopic osteochondrosis severity score. NS = Not significant at a value of $P \leq 0.05$. Lesion = Total osteochondrosis lesion count. Radiographic = Total radiographic osteochondrosis score for the femoropatellar-femorotibial (ie, stifle) and tibiotarsal (ie, hock) joints.

lesions do not develop in horses after 7 months of age, analysis of our results confirmed that radiography is best used after 9 months of age to assess the severity of osteochondrosis lesions that are likely to persist beyond the first year after birth.

Serum osteocalcin concentrations, a putative biomarker of bone formation and mineralization, were significantly correlated with severity of osteochondrosis in foals during the first year after birth. However, probably as a result of the nature of the osteochondrosis lesion in horses in which a large number resolve during the early neonatal period, there was a different relationship between the osteocalcin concentrations and osteochondrosis severity for foals assessed at 5 months of age, compared with the relationship for foals examined at 11 months of age. Whereas serum osteocalcin concentrations were positively correlated with macroscopic osteochondrosis severity and number of lesions at 5 months of age, concentrations were negatively correlated with these disease variables at 11 months of age. These findings in our foals with naturally developing disease support those of a study³⁶ in which increased serum osteocalcin concentrations were detected in 5-month-old foals that developed osteochondrosis secondary to experimentally induced copper deficiency and those in another study³⁷ in which lower serum osteocalcin concentrations were detected in a 16-month-old foal with multiple osteochondrosis lesions.

We also detected significant positive relationships between concentrations of biomarkers of collagen degradation in bone and cartilage (ie, COL2-3/4C_{short}, 234CEQ, and CTx1) and severity of osteochondrosis at 5 months of age. These significant positive relationships between serum concentrations of fragments of type-I and -II collagen degradation bearing the COL2-3/4C_{short}, 234CEQ, and CTx1 neopeptides and osteochondrosis severity scores suggest substantial collagenase-induced turnover of collagen during the development of early osteochondrosis lesions (ie, 5 months of age). Only serum COL2-3/4C_{short} concentrations remained significantly correlated with severity of osteochondrosis at 11 months of age, and similar to osteocalcin concentrations, they were negatively correlated with osteochondrosis severity. Loss (234CEQ and CTx1) and reversal (COL2-3/4C_{short} and osteocalcin) of the significant relationships between concentrations of these biomarkers and osteochondrosis severity at 11 months of age may be a reflection of the substantial amounts of repair and resolution of osteochondrosis lesions (severity and number) evident from 5 to 11 months of age.⁶ The findings in the 11-month-old foals implied decreased bone collagen turnover (CTx1 and COL2-3/4C_{short} concentrations) and mineralization (osteocalcin concentrations) with increasing osteochondrosis severity in foals with permanent lesions. Moreover, the loss at 11 months of age of the positive relationship between serum concentrations of CTx1 and severity of osteochondrosis evident at 5 months of age may have been attributable to the type-I collagen molecules in the more severe and permanent lesions at 11 months having fewer cross-links than are found in normal bone. Reduced collagen cross-linking in carti-

lage and bone was detected in horses with osteochondrosis attributable to copper deficiency,^{7,10} and although not significant, we did detect negative overall correlations between CTx1 concentrations and osteochondrosis severity scores and CTx1 concentrations and lesion counts (Table 1).

It has been suggested that there are abnormalities in type-II collagen of cartilage in humans,³ pigs,^{38,39} and horses^{7,10} with osteochondrosis. In the study reported here, there was also evidence of increased collagen production in cartilage as indicated by the significant relationship between CII concentrations and osteochondrosis severity for the foals evaluated at 11 months of age. These findings support the results of another study¹⁶ in which concentrations of CII in synovial fluid were significantly increased in young horses with osteochondrosis. Because the typical osteochondrosis lesion in horses is an osteochondral fragment within a subchondral bone defect, analysis of our findings also supported those of another study²¹ in which increased serum CII concentrations were found in horses with osteochondral fragmentation involving the carpal joints. Similar increases in serum concentrations of the CII have been detected in humans with rapidly progressive rheumatoid arthritis,²⁹ and increased concentrations of CII have been detected in osteoarthritic cartilage in humans.⁴⁰

The increased synthesis of type-II collagen, as indicated by increased concentrations of CII in the aforementioned orthopedic conditions, may be in response to increased damage to type-II collagen. Increased cleavage and loss of type-II collagen in cartilage have been described in humans^{23,41} and horses²² with osteoarthritis. In another report,⁴² researchers described an increase in cleavage of type-II collagen by collagenases by use of a COL2-3/4C_{short} ELISA for *ex vivo* cultures of articular cartilage obtained from osteochondrosis lesions of horses, compared with cleavage of normal articular cartilage explants. As mentioned previously, we did detect a significant relationship between serum concentrations of 234CEQ and severity of osteochondrosis in the foals at 5 months of age. This supports the concept that increases in type-II collagen production suggested by significant increases in serum CII concentrations with increasing osteochondrosis severity, especially at 5 months of age, is in response to increased degradation of type-II collagen in these early osteochondrosis lesions. The significant relationship between type-II collagen synthesis and severity of osteochondrosis in the foals at 11 months of age may also have been in response to supporting subchondral bone that had increased fragility as a result of insufficient turnover of type-I collagen (COL2-3/4C_{short}), cross-linking (CTx1), or mineralization (osteocalcin).

For the proteoglycan biomarkers analyzed in the study reported here, there have been conflicting reports on the differences in concentrations of CS-846 in body fluids between clinically normal horses and horses with osteochondral disease. Compared with concentrations in clinically normal horses, significantly lower CS-846 concentrations have been measured in synovial fluid obtained from young horses with osteo-

chondrosis¹⁶ and significantly higher concentrations have been measured in synovial fluid and serum samples obtained from older horses with osteochondral fragmentation.²¹ This biomarker was not significantly correlated with macroscopic osteochondrosis severity scores or number of lesions for any of the regression models in the study reported here, but it was significantly correlated overall with lesion count and total radiographic scores (Table 1). In contrast to those other published reports,^{16,21} our study did not include a control group of unaffected foals. Therefore, we cannot use the results of the study reported here to comment on or provide comparison of differences between clinically normal horses and horses with osteochondral disease.

We did not detect significant correlations between serum concentrations of total sGAGs and any of the osteochondrosis severity scores, which suggested no change in proteoglycan turnover. This is supported by results of another study⁴² in which investigators did not detect an increase in proteoglycan degradation in *ex vivo* explant cultures of articular cartilage obtained from osteochondrosis lesions of horses, compared with proteoglycan degradation in articular cartilage explants obtained from clinically normal horses. In fact, there was evidence of decreased sGAG turnover with increasing disease severity in the foals of the study reported here at 5 months of age, but this relationship disappeared by 11 months of age.

A limitation of the study reported here was that all foals were genetically predisposed to osteochondrosis and all foals had a lesion at some point during the study. Moreover, during the first 5 months after birth, the foals were subjected to differing exercise regimens, even though exercise did not affect the number or severity of osteochondrosis lesions at 5 months of age.¹⁹ Additional studies with a population of foals that include those free of osteochondrosis and with similar amounts of exercise throughout the first year after birth would be appropriate. This will allow for confirmation of our findings by including foals without disease (osteochondrosis severity score of 0). It will also enable comment on the potential of any of these biomarkers for use as an early diagnostic tool to detect osteochondrosis. We must be cautious about conclusions based on the serum concentrations of biomarkers of skeletal metabolism, especially when there are only solitary lesions identified within a single joint, as may happen in osteochondrosis. Many of the molecules measured in serum may represent the response of an entire joint to the lesion (ie, arthritis) or a systemic response to the condition with contributions from other sources, such as with byproducts of metabolism of type-I collagen that may arise from skin, bone, tendons, and ligaments.

Analysis of the findings of the study reported here suggested that radiographic evaluation of the hock and stifle joints throughout the first year after birth is a valuable tool for use in assessing the severity of osteochondrosis in horses. Its ability to detect osteochondrosis and determine the severity of early osteochondrosis lesions is strengthened by evaluation of serum concentrations of osteocalcin, a putative biomarker of bone

formation and mineralization. In combination, results of radiography and measurement of osteocalcin concentrations at 1 month of age predicted approximately two-thirds of the variability in the number and severity of lesions at 5 months of age. However, because many of the lesions radiographically identified at 1 month of age resolved by 11 months of age, a different relationship was identified between results of radiography and serum biomarker concentrations used for assessing severity of disease at 11 months of age. Whereas serum osteocalcin concentrations were negatively correlated with osteochondrosis severity at 11 months of age, results of radiography at 9 and 11 months of age combined with the serum CPII concentrations, especially at 5 months of age, were the best indicators of the severity of the more permanent lesions. Therefore, we suggest that some serum biomarkers of bone and cartilage metabolism have a role as putative indicators of horses with severe osteochondrosis lesions that are unlikely to resolve. With this knowledge, early intervention and monitoring of treatment response may be possible through serial assay of serum concentrations of specific biomarkers of cartilage and bone metabolism, coupled with radiography, in young developing horses with osteochondral disease.

^aPICP, DiaSorin Inc, Stillwater, Minn.

^bCPII assay, Ibex Diagnostics, Montreal, QC, Canada.

^cSerum CrossLaps One-Step ELISA, Osteometer BioTech A/S, Herlev, Denmark.

^dNovocalcin, Metra Biosystems, Mountain View, Calif.

^eCS-846 assay, Ibex Diagnostics, Montreal, QC, Canada.

^fSAS, version 8e, SAS Institute Inc, Cary, NC.

References

1. Stanescu V, Stanescu R, Maroteaux P. Pathogenic mechanisms in osteochondroplasias. *J Bone Joint Surg Am* 1984;66A:817-836.
2. Olsson SE, Reiland S. The nature of osteochondrosis in animals. Summary and conclusions with comparative aspects on osteochondritis dissecans in man. *Acta Radiol Suppl* 1978;358:299-306.
3. Mubarak SJ, Carroll NC. Juvenile osteochondrosis dissecans of the knee: etiology. *Clin Orthop* 1981;157:200-211.
4. Jeffcott LB, Henson FMD. Studies on growth cartilage in the horse and their application to aetiopathogenesis of dyschondroplasia (osteochondrosis). *Vet J* 1998;156:177-192.
5. McIntosh SC, McIlwraith CW. Natural history of femoropatellar osteochondrosis in three crops of Thoroughbreds. *Equine Vet J Suppl* 1993;16:54-61.
6. Dik KJ, Enzerink E, van Weeren PR. Radiographic development of osteochondral abnormalities, in the hock and stifle of Dutch Warmblood foals, from age 1 to 11 months. *Equine Vet J Suppl* 1999;31:9-15.
7. Bridges CH, Harris ED. Experimentally induced cartilaginous fractures (osteochondritis dissecans) in foals fed low-copper diets. *J Am Vet Med Assoc* 1988;193:215-221.
8. Henson FM, Davies ME, Jeffcott LB. Equine dyschondroplasia (osteochondrosis)—histological findings and type VI collagen localization. *Vet J* 1997;154:53-62.
9. Hernandez-Vidal G, Jeffcott LB, Davies ME. Immunolocalization of cathepsin B in equine dyschondroplastic articular cartilage. *Vet J* 1998;156:193-201.
10. Hurtig MB, Green SL, Dobson H, et al. Correlative study of defective cartilage and bone growth in foals fed a low-copper diet. *Equine Vet J Suppl* 1993;16:66-73.
11. Lillich JD, Bertone AL, Malesud CJ, et al. Biochemical, histochemical and immunohistochemical characterization of distal tibial osteochondrosis in horses. *Am J Vet Res* 1997;58:89-98.
12. Semevolos SA, Nixon AJ, Brower-Toland BD. Changes in molecular expression of aggrecan and collagen types I, II, and X,

insulin-like growth factor-1, and transforming growth factor- β 1 in articular cartilage obtained from horses with naturally acquired osteochondrosis. *Am J Vet Res* 2001;62:1088–1094.

13. Brama PAJ, TeKoppele JM, Beekman B, et al. Matrix metalloproteinase activity in equine synovial fluid: influence of age, osteoarthritis, and osteochondrosis. *Ann Rheum Dis* 1998;57:697–699.

14. Brama PAJ, TeKoppele JM, Beekman B, et al. Influence of development and joint pathology on stromelysin enzyme activity in equine synovial fluid. *Ann Rheum Dis* 2000;59:155–157.

15. Clegg PD, Coughlan AR, Riggs CM, et al. Matrix metalloproteinases 2 and 9 in equine synovial fluids. *Equine Vet J* 1997;29:343–348.

16. Laverty S, Ionescu M, Marcoux M, et al. Alterations in cartilage type-II procollagen and aggrecan contents in synovial fluid in equine osteochondrosis. *J Orthop Res* 2000;18:399–405.

17. Todhunter RJ, Fubini SL, Freeman KP, et al. Concentration of keratan sulfate in plasma and synovial fluid from clinically normal horses and horses with joint disease. *J Am Vet Med Assoc* 1997;210:369–374.

18. van Weeren PR, Barneveld A. Study design to evaluate the influence of exercise on the development of the musculoskeletal system of foals up to age 11 months. *Equine Vet J Suppl* 1999;31:4–8.

19. van Weeren PR, Barneveld A. The effect of exercise on the distribution and manifestation of osteochondrotic lesions in the Warmblood foal. *Equine Vet J Suppl* 1999;31:16–25.

20. Price JS, Jackson B, Eastell R, et al. Age related changes in biochemical markers of bone metabolism in horses. *Equine Vet J* 1995;27:201–207.

21. Frisbie DD, Ray CS, Ionescu M, et al. Measurement of synovial fluid and serum concentrations of the 846 epitope of chondroitin sulfate and of carboxy propeptides of type II procollagen for diagnosis of osteochondral fragmentation in horses. *Am J Vet Res* 1999;60:306–309.

22. Billingham RC, Buxton EM, Edwards MG, et al. Use of an antineoepitope antibody for identification of type-II collagen degradation in equine articular cartilage. *Am J Vet Res* 2001;62:1031–1039.

23. Billingham RC, Dahlberg L, Ionescu M, et al. Enhanced cleavage of type II collagen by collagenases in osteoarthritic articular cartilage. *J Clin Invest* 1997;99:1534–1545.

24. Billingham RC, Ionescu M, Poole AR. Immunoassay for collagenase-mediated cleavage of types I and II collagens. In: Clark I, ed. *Methods in molecular biology*, 151. *Matrix metalloproteinase protocols*. Totowa, NJ: Humana Press, 2001;457–472.

25. Billingham RC, O'Brien K, Poole AR, et al. Inhibition of articular cartilage degradation in culture by a novel nonpeptidic matrix metalloproteinase inhibitor. *Ann N Y Acad Sci* 1999;878:594–597.

26. Boskey AL. Noncollagenous matrix proteins and their role in mineralization. *Bone Miner* 1989;6:111–123.

27. Fenton JI, Orth MW, Chlebek-Brown KA, et al. Effect of longeing and glucosamine supplementation on serum markers of bone and joint metabolism in yearling quarter horses. *Can J Vet Res* 1999;63:288–291.

28. Lohmander LS, Ionescu M, Jugessur H, et al. Changes in joint cartilage aggrecan after knee injury and in osteoarthritis. *Arthritis Rheum* 1999;42:534–544.

29. Mannson B, Carey D, Alini M, et al. Cartilage and bone metabolism in rheumatoid arthritis: differences between rapid and slow progression of disease identified by serum markers of cartilage metabolism. *J Clin Invest* 1995;95:1071–1077.

30. Poole AR, Ionescu M, Swan A, et al. Changes in cartilage metabolism in arthritis are reflected by altered serum and synovial fluid levels of the cartilage proteoglycan aggrecan: implications for pathogenesis. *J Clin Invest* 1994;94:25–33.

31. Rizkalla G, Reiner A, Bogoch E, et al. Studies of the articular cartilage proteoglycan aggrecan in health and osteoarthritis: evidence for molecular heterogeneity and extensive molecular changes in disease. *J Clin Invest* 1992;90:2268–2277.

32. Farndale RW, Buttle DJ, Barrett AJ. Improved quantitation and discrimination of sulphated glycosaminoglycans by use of dimethylmethylene blue. *Biochim Biophys Acta* 1986;883:173–177.

33. Billingham RC, Brama PAJ, van Weeren PR, et al. Significant exercise-related changes in the serum levels of two biomarkers of collagen metabolism in young horses. *Osteoarthritis Cartilage* 2003;11:760–769.

34. Jeffcott LB. Osteochondrosis in the horse—searching for the key to pathogenesis. *Equine Vet J* 1991;23:331–338.

35. Carlson CS, Cullins LD, Meuten DJ. Osteochondrosis of the articular-epiphyseal cartilage complex in young horses: evidence for a defect in cartilage blood supply. *Vet Pathol* 1995;32:641–647.

36. Hurtig MB, Green SL, Dobson H, et al. Defective bone and cartilage in foals fed a low-copper diet, in *Proceedings*. Am Assoc Equine Pract 1991;36:637–643.

37. Girard C, Lepage OM, Rossier Y. Multiple vertebral osteochondrosis in a foal. *J Vet Diagn Invest* 1997;9:436–438.

38. Carlson CS, Hilley HD, Henrikson CK, et al. The ultrastructure of osteochondrosis of the articular-epiphyseal cartilage complex in growing swine. *Calcif Tissue Int* 1986;38:44–51.

39. Ekman S, Rodriguez-Martinez H, Plöen L. Morphology of normal and osteochondrotic porcine articular-epiphyseal cartilage: a study in the domestic pig and minipig of wild hog ancestry. *Acta Anat* 1990;139:239–253.

40. Nelson F, Dahlberg L, Laverty S, et al. Evidence for altered synthesis of type II collagen in patients with osteoarthritis. *J Clin Invest* 1998;102:2115–2125.

41. Dahlberg L, Billingham RC, Manner P, et al. Selective enhancement of collagenase-mediated cleavage of resident type II collagen in cultured osteoarthritic cartilage and arrest with a synthetic inhibitor that spares collagenase I (matrix metalloproteinase 1). *Arthritis Rheum* 2000;43:673–682.

42. Laverty S, O'Kouneff S, Ionescu M, et al. Excessive degradation of type II collagen in articular cartilage in equine osteochondrosis. *J Orthop Res* 2002;20:1282–1289.