

Glomerular lesions in dogs infected with *Leishmania* organisms

Andrea Zatelli, DMV; Michele Borgarelli, DMV; Roberto Santilli, DMV; Ugo Bonfanti, DMV; Evandro Nigrisoli, MD; Renato Zanatta, DMV; Alberto Tarducci, DMV; Aurelio Guarraci, DMV

Objective—To histologically identify glomerular lesions in dogs infected with *Leishmania* organisms.

Animals—41 dogs (17 sexually intact males and 14 sexually intact and 10 ovariectomized females) that had positive results when tested for leishmaniasis as determined by use of serologic evaluation (indirect fluorescent antibody test, titers of 1:80 to 1:640) and direct microscopic identification of the protozoal organisms.

Procedure—Urine samples were collected by use of cystocentesis and examined by qualitative SDS-agarose gel electrophoresis (AGE). All dogs had nonselective (glomerular) or mixed (glomerular and tubular) proteinemia. Specimens were obtained from each dog during ultrasound-assisted renal biopsy and used for histologic examination. Each specimen was stained with H&E, periodic acid-Schiff, Goldner's trichrome, methenamine silver, and Congo Red stains. Specimens were adequate for evaluation when they contained at least 5 glomeruli/section, except for specimens stained with Congo Red in which 1 glomerulus/section was adequate.

Results—Examination of renal biopsy specimens revealed various glomerular lesions in all dogs and interstitial or tubular (or both) lesions in 23 of 41 (55%) dogs.

Conclusions and Clinical Relevance—Glomerular lesions that develop in dogs during infection with *Leishmania* organisms can be classified histologically as mesangial glomerulonephritis, membranous glomerulonephritis, membranoproliferative glomerulonephritis, and focal segmental glomerulonephritis. Tubulointerstitial histopathologic conditions were not observed as the primary lesion, despite being evident in 23 of 41 (55%) dogs. Use of SDS-AGE for qualitative evaluation of proteinuria and successive collection of specimens during renal biopsies following diagnosis of nonselective glomerular proteinuria provides the possibility for early identification of renal lesions. (*Am J Vet Res* 2003;64:558–561)

Leishmaniasis is endemic in the Mediterranean area, including Italy, and is caused by the protozoan

Received September 4, 2002.

Accepted January 3, 2003.

From the Private Practice Clinica Veterinaria Pirani, Via Majakowski, 2/N 42100 Reggio Emilia, Italy (Zatelli); the Department of Veterinary Clinical Medicine, School of Veterinary Medicine, University of Torino, Italy (Borgarelli, Zanatta, Tarducci); Clinica Veterinaria Malpensa, Via Palestro, 21 Samarate (VA), Italy (Santilli); Clinica Veterinaria Gran Sasso, Via Donatello, 26 Milano, Italy (Bonfanti); Sessione Istopatologia ed Anatomia Speciale, Ospedale S. Maria Nuova, Reggio Emilia, Italy (Nigrisoli); and Ambulatorio Veterinario Guarraci-Becthle, Via dei Quartieri, 96 Palermo, Italy (Guarraci).

Address correspondence to Dr. Zatelli.

Leishmania donovani infantum. The disease is characterized by systemic reticuloendotheliosis and often causes a polymorphic clinical picture in which renal pathologic conditions are the principal cause of death. Renal lesions encountered during the course of leishmaniasis in humans can be classified histologically as **membranous glomerulonephritis (MmGN)**, **membranoproliferative glomerulonephritis (MpGN)**, **mesangial glomerulonephritis (MGN)**, **focal segmental glomerulonephritis (FSGN)**, and acute and chronic interstitial nephrosis.^{1,2} In dogs, histopathologic glomerular lesions correspond with those reported³⁻⁵ in humans, although with differing relative frequencies. Glomerular lesions that characterize renal involvement in dogs with leishmaniasis determine the appearance of proteinuria that varies from normal to pathologic and, furthermore, does not correlate with the type of histopathologic glomerular lesions.³ Qualitative evaluation of urinary proteins assumes a central role in early diagnosis of pathologic glomerular conditions. Use of SDS-agarose gel electrophoresis (AGE) permits the identification of urinary proteins that have molecular masses from 9 kD (ie, β_2 microglobulin) to 900 kD (ie, α_2 macroglobulin). The method consists of the separation of single proteinic fractions in an agarose gel on the basis of mass and independent of charge; interference of the migration of smaller proteins by larger proteins is eliminated.

In dogs that lack histopathologic lesions, qualitative evaluation of proteinuria does not permit the identification of separate protein bands, nor does it permit the exclusive identification of selective glomerular proteinuria characterized solely by the detection of albumin.^b Nonselective glomerular proteinuria (albumin bands and concomitant detection of 1 or more bands that have molecular masses > 69 kD) in inert urine sediment is theoretically attributable to glomerular lesions. Following the assessment of laboratory tests that may be indicative of histopathologic glomerular lesions, diagnostic methods involve identification of the underlying lesion. For renal analysis, conventional histologic examination is the method that provides the greatest sensitivity and specificity. Whenever necessary, other techniques are used, including immunohistochemical analysis, immunofluorescent analysis, and electron microscopic examination. The objective of the study reported here was to identify histopathologic glomerular lesions in dogs infected with *Leishmania* organisms and determine their possible correlation with patterns of urinary proteinuria.

Materials and Methods

Animals—Eighty-nine dogs that had positive results when tested for leishmaniasis by use of the **indirect fluorescent antibody (IFA)** test were considered for inclusion in the study.

Titers of the dogs ranged from 1:80 to 1:640. Forty-eight dogs were excluded from the study on the basis of the following criteria: lack of direct confirmation of the protozoa, positive result when tested for *Ehrlichia canis* by use of an IFA test, negative result on SDS-AGE, or positive result for selective glomerular proteinuria. Forty-one dogs had positive results for the protozoa as determined by direct cytologic examination of biopsy specimens obtained from the lymph nodes, spleen, liver, or bone marrow and stained with May-Grunwald-Giemsa stain, had negative results for *E canis* when tested by use of an IFA test, and had positive results on SDS-AGE for nonselective glomerular proteinuria or mixed proteinuria; therefore, these dogs were included in the study. The 41 dogs comprised 17 sexually intact males, 14 sexually intact females, and 10 ovariohysterectomized females and ranged from 1 to 13 years of age.

Laboratory analyses—A urine sample (10 mL) was collected from each dog by use of ultrasound-assisted cystocentesis. Urine samples that were used for qualitative determination of proteinuria were treated by the addition of 1 μ L of 1% sodium azide/mL of urine and stored in sterile containers at 4° to 8°C. Qualitative assays of proteinuria as determined by the use of SDS-AGE were conducted within 7 days after collection of urine samples. All examinations were performed at a single laboratory. Qualitative evaluation of proteinuria by the use of SDS-AGE is based on treatment that provides all proteins with a negative charge proportional to their mass followed by electrophoretic separation of urinary proteins on the basis of mass. The limit of sensitivity for each fraction was 15 mg/L. Several proteins can be identified by the use of this technique, including β_2 -microglobulin, lysozyme, retinol binding protein, κ and λ light chains, α_1 -microprotein, dimers of light chains, albumin, transferrin, IgG, IgA, haptoglobin, and α_2 -macroglobulin.

Hematologic examinations (hemochromocytometric and hemocoagulative), abdominal ultrasonographic examination, and determination of systolic pressure by use of Doppler analysis^c were performed on each dog. Alterations in coagulation that were considered incompatible with biopsy procedures included the following: prothrombin time > 12 seconds, activate partial thromboplastin time > 19 seconds, fibrinogen concentration < 100 mg/dL, inadequate platelet counts, or increased bleeding time.^{6,7} Hypertension was not considered incompatible with renal biopsy as long as the hemocoagulative results were unaltered and the dog had normal bleeding times and adequate platelet counts. Administration of aspirin or anti-inflammatory steroids was suspended at least 5 days prior to the biopsy procedure.⁷

Collection of renal biopsy specimens—Renal biopsy specimens were obtained from each dog by the use of ultrasound-assisted biopsy. Specimens were used for the identification of primary histopathologic lesions.

Food was withheld from each dog for 12 hours prior to the biopsy. Dogs were sedated and placed in dorsal recumbency. The abdominal area was shaved and sterilized in accordance with routine surgical procedures. Biopsies were performed with the assistance of real-time ultrasonography. Biopsies were performed with a semi-automatic apparatus^d in 37 dogs and an automatic apparatus^e in 4 dogs. Biopsy specimens were fixed in neutral-buffered 10% formalin.

Histologic examination—Sections of each renal biopsy specimen were stained with H&E, periodic acid-Schiff (PAS), Goldner's trichrome, methenamine silver, and Congo Red stains. The PAS stain was used to best identify integrity of the basement membrane, detect location of deposits, and delineate crescents from the underlying compressed glomerular tuft. Trichrome stain was used to highlight areas of fibrosis or sclerosis, fuchsinophilic deposits, and duplication or thickening of the basement membrane.

Methenamine silver stain was used to outline basement membranes of the tubules and glomeruli and areas of sclerosis, enable the best assessment of severity of overall renal damage, and highlight abnormalities in glomerular basement membranes (GBMs) such as spikes and duplication. Congo Red stain was used to detect deposits of amyloid.

Sections of biopsy specimens were considered adequate for histologic examination when they contained at least 5 glomeruli/section. The exception was for sections stained with Congo Red in which 1 glomerulus/section was considered adequate for a correct diagnosis.

Various lesions were identified during histologic examination of the renal biopsy specimens. For MmGN, formation of immune complexes is initiated in the subepithelial side of the GBM.⁸ Pathologic changes of MmGN are primarily within the GBM, resulting in enlargement of the glomerular tuft with thickening of the capillary basement membrane but no cellular proliferation or inflammatory infiltration.⁹ The glomeruli typically have characteristic and uniform changes.

For MpGN, immune complexes form in the mesangium as well as the endothelial or epithelial sides of the GBM.⁸ Glomeruli are enlarged; there is thickening of the GBM with a tram-track appearance caused by mesangial interposition along the capillary wall in combination with mesangial, epithelial, or endothelial proliferation.⁹ The increase in cellularity within each glomerular lobule creates an accentuation of the lobular pattern, and the glomeruli typically have characteristic and uniform changes.

Mesangioproliferative glomerulonephritis is the result of deposition of large immune complexes in the mesangium. The World Health Organization¹ has defined MGN as an essentially uniform increase in mesangial cells (with clusters of 4 or more per mesangial area) in all or nearly all glomeruli, and cell proliferation may be accompanied by an increase in the mesangial matrix.

Focal segmental glomerulonephritis is identified when many glomeruli are apparently normal or have slight or equivocal increases in mesangial cells. Affected glomeruli contain segmental areas of sclerosis, which often adhere to the capsule. Lesions often contain large, eosinophilic deposits referred to as hyaline.⁹

Results

Of 41 dogs, 39 (95.1%) had nonselective glomerular proteinuria as evidenced by detection of albumin, transferrin, and IgG. Mixed (tubular and glomerular)

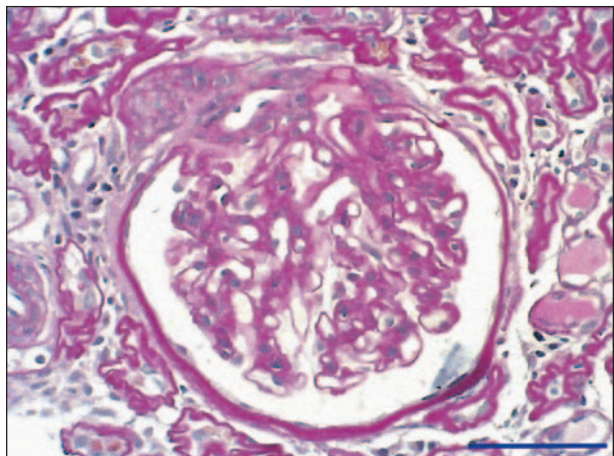


Figure 1—Photomicrograph of a section of a renal biopsy specimen obtained from a representative dog with leishmaniosis, revealing evidence of mesangial glomerulonephritis. Notice the diffuse mesangial proliferation and a minimum increase in cellularity. Periodic acid-Schiff stain; bar = 50 μ m.

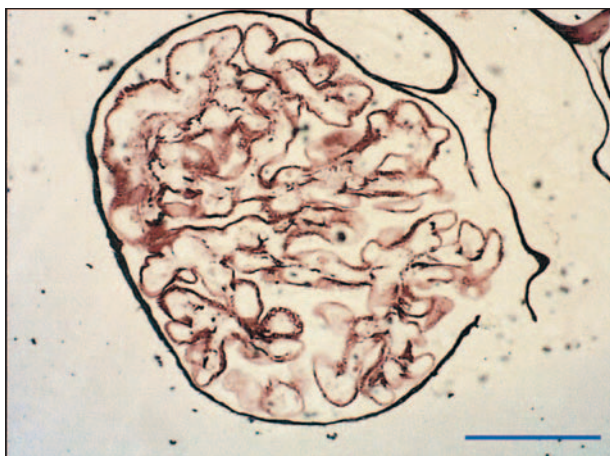

Figure 2—Photomicrograph of a section of a renal biopsy specimen obtained from a representative dog with leishmaniasis, revealing evidence of membranous glomerulonephritis. Notice that the glomerular basement membrane is moderately thickened and coarsely vacuolated. Methenamine silver stain; bar = 50 μ m.

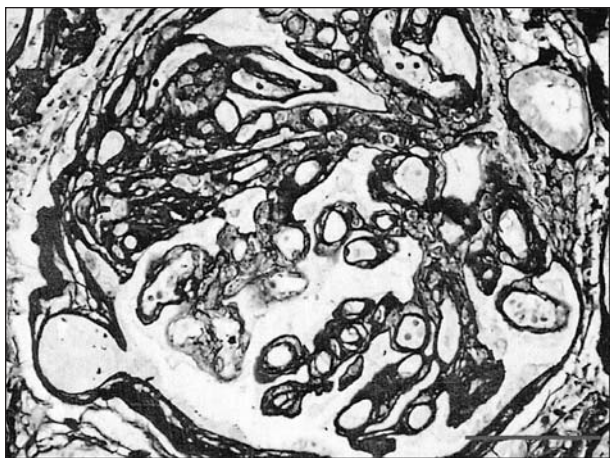


Figure 3—Photomicrograph of a section of a renal biopsy specimen obtained from a representative dog with leishmaniasis, revealing evidence of membranoproliferative glomerulonephritis. Notice the mesangial proliferation and diffuse duplication of the basement membranes. Methenamine silver stain; bar = 50 μ m.

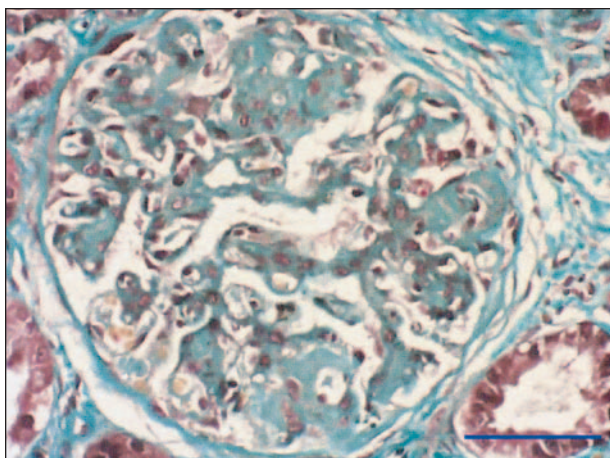


Figure 4—Photomicrograph of a section of a renal biopsy specimen obtained from a representative dog with leishmaniasis, revealing evidence of focal segmental glomerulonephritis. Notice that the glomerular tuft has segmental sclerosis. Goldner's trichrome stain; bar = 50 μ m.

proteinuria was detected in 2 (4.9%) dogs; the glomerular pattern was represented by detection of albumin, transferrin, and IgG. Each of the 41 biopsy specimens was considered adequate for evaluation, because there were at least 5 glomeruli/section.

The following histopathologic lesions were identified: MGN, 9 of 41 (21.9%) dogs (Fig 1); MmGN, 11 of 41 (26.8%) dogs (Fig 2); MpGN, 12 of 41 (29.3%) dogs (Fig 3); and FSGN, 8 of 41 (19.5%) dogs (Fig 4). The renal biopsy specimen from 1 (2.4%) dog did not have visible histopathologic lesions; thus, the biopsy was repeated, and FSGN was found in the second renal biopsy specimen obtained from that dog.

Discussion

In dogs, glomerular lesions that develop during leishmaniasis can be histologically classified as MmGN, MpGN, MGN, and FSGN. Substantial differences in the frequency of these histopathologic entities have been cited by other authors.^{3,5} In 1 study,³ the predominant glomerular lesions were MGN, whereas MmGN was the most frequent lesion reported in another study,⁴ and MpGN was the most common lesions reported in another study.⁵ In dogs, acute or chronic tubulointerstitial lesions also have differing incidences, ranging from always evident⁵ to almost always evident, even for diverse grades, and correlated with MpGN for the more severe forms. In the study reported here, the prevalence of MmGN, MpGN, MGN, and FSGN was distributed almost equally. Glomerular lesions⁷ are typically primary lesions detected during the course of immune-mediated pathologic conditions, such as those encountered in dogs with leishmaniasis.^{3,5,10-12}

Qualitative analysis of proteinuria by use of SDS-AGE minimizes the interference of the migration of proteins that have a low molecular mass by proteins that have a high molecular mass. This is important during the course of nonselective glomerular proteinuria, which is characterized by the loss of albumin and 1 or more of the following proteic components: transferrin, IgG, IgA, haptoglobin, or α_2 macroglobulin. The SDS-AGE is a specific and sensitive method for identification of glomerular lesions. Use of SDS-AGE for the qualitative evaluation of proteinuria and successive samples obtained by renal biopsy following a diagnosis of nonselective glomerular proteinuria provides the possibility of early identification of renal lesions. Moreover, it does not prejudice histologic diagnosis with functional variables that are of relatively low sensitivity and often found in late stages of disease, including increased serum concentrations of creatinine and urea and proteinuria.¹³ All dogs with glomerular damage were homogeneous with respect to their pattern of glomerular proteinuria, because they had positive results for the same bands. This homology does not allow consideration of SDS-AGE for use in distinguishing among glomerular disorders and confirms that histopathologic characteristics are the preferred means for differentiating glomerular diseases after evaluation of abnormal proteinuria has been assessed qualitatively. The SDS-AGE appears to be an extremely valid test for identification of glomerular lesions, but it has little potential for use in distinguish-

ing between various diseases. For early diagnosis of renal histopathologic changes in dogs with leishmaniosis,^{6,14-16} sensitivity of SDS-AGE for the identification of glomerular proteinuria and successive ultrasound-assisted renal biopsy currently represent the best tools in veterinary medicine.

^aZatelli A, Bussadori C, Doménech O, et al. Lesiones histopatológicas glomerulares y correlación clínica en el curso de la leishmaniosis, in *Proceedings*. 36th Asociación de Veterinarios Españoles Especialistas en Pequeños Animales. Natl Cong, 2001.

^bZatelli A, Bonfanti U. Qualitative determination of proteinuria by SDS-PAGE in the healthy dog (abstr). *J Vet Intern Med* 2002;3:389.

^cUltrasonic Doppler flow detector, model 811-BTS, Parks Medical Electronics Inc, Aloha, Ore.

^dTemno biopsy device T 189, 18 gauge × 9-cm needle, Allegiance Healthcare Corp, McGaw Park, Ill.

^ePRO-MAG automatic biopsy system, 18 gauge × 15-cm needle, AMEDIC, Sollentuna, Sweden.

^fChurg J, Sobin LH. *Renal disease: classification and atlas of glomerular disease*. Tokyo: Igaku-Shoin, 1982.

References

1. Dutra M, Martinelli R, de Carvalho EM, et al. Renal involvement in visceral leishmaniasis. *Am J Kidney Dis* 1985;6:22.
2. Cavallo T. Tubulointerstitial nephritis. *Heptinstall's pathology of the kidney*. 5th ed. Philadelphia: Lippincott-Raven Publishers, 1998; 667-723.
3. Poli A, Abramo F, Mancianti F, et al. Renal involvement in canine leishmaniasis. *Nephron* 1991;57:444-452.
4. Benderitter T, Casanova P, Moller K, et al. Glomerulonephritis in dogs with leishmaniasis. *Ann Trop Med Parasitol* 1988;82: 335-341.

5. Koutinas AF, Kontos V, Kaldrimidou H, et al. Canine leishmaniasis associated nephropathy: a clinical, clinicopathologic and pathologic study in 14 spontaneous cases with proteinuria. *Bull HVMS* 1994;2:131-140.

6. Iversen P, Brun C. Aspiration biopsy of the kidney. *Am J Med* 1951;11:324-330.

7. Tomura S, Tsutani K, Sakuma A, et al. Discriminant analysis in renal histological diagnosis of primary glomerular disease. *Clin Nephrol* 1985;23:55-62.

8. Day MJ. Immune-mediated renal and reproductive disease. In: Day MJ, ed. *Clinical immunology of the dog and cat*. 1st ed. Ames, Iowa: Iowa State University Press, 1999;171-180.

9. Jennette JC, Olson JL, Schwartz MM, et al. Glomerular diseases. *Heptinstall's pathology of the kidney*. 5th ed. Philadelphia: Lippincott-Raven Publishers, 1998;181-625.

10. Minkus G, Reusch C, Horauf A, et al. Evaluation of renal biopsies in cats and dogs—histopathology in comparison with clinical data. *J Small Anim Pract* 1994;35:465-472.

11. Nieto CG, Navarrete I, Habela M, et al. Pathological changes in kidneys of dogs with natural *Leishmania* infection. *Vet Parasitol* 1992;45:33-47.

12. Lopez R, Lucena R, Novales M, et al. Circulating immune complexes and renal function in canine leishmaniasis. *Zentralbl Veterinarmed [B]* 1996;8:469-474.

13. Sideris V, Papadopoulou G, Dotsika E, et al. Asymptomatic canine leishmaniasis in Greater Athens area, Greece. *Eur J Epidemiol* 1999;3:271-276.

14. Orndorff GR, Cooper BA, Smith W, et al. Canine visceral leishmaniasis in Sicily. *Mil Med* 2000;1:29-32.

15. Blavier A, Keroack S, Denerolle P, et al. Atypical forms of canine leishmaniasis. *Vet J* 2001;2:108-120.

16. Ciaramella P, Oliva G, Luna RD, et al. A retrospective clinical study of canine leishmaniasis in 150 dogs naturally infected by *Leishmania infantum*. *Vet Rec* 1997;21:539-543.