

# Effects of a bioactive glass on healing of closed skin wounds in dogs

Robert L. Gillette, DVM, MSE; Steven F. Swaim, DVM, MS; Eva A. Sartin, DVM, PhD;  
Dino M. Bradley, DVM, PhD; Shindok L. Coolman, MS

**Objective**—To determine effects of intraincisional bioactive glass on healing of sutured skin wounds in dogs.

**Animals**—9 purpose-bred mature female Beagles.

**Procedure**—3 small matched bilateral (treated vs control) full-thickness truncal skin incisions were made and sutured. Treated wounds received intraincisional particulate bioactive glass prior to closure. Laser Doppler perfusion imaging was used to assess percentage change in tissue perfusion 3 and 5 days after incision on 1 set of 2 matched wounds, and skin and subcutaneous tissue-cutaneous trunci breaking strength were assessed at 5 days. The other 2 sets of wounds were used for histologic evaluation at 5 and 21 days, respectively.

**Results**—Subjective signs of gross inflammatory reaction were not detected in treated or control wounds. At 5 days, median subcutaneous tissue-cutaneous trunci breaking strength was significantly higher in treated wounds than in control wounds (188.75 vs 75.00 g). At 5 days, median scores were significantly higher for neutrophils (1 vs 0), macrophages (2 vs 1), and necrosis (1 vs 0) for treated wounds than for control wounds. At 21 days, median macrophage scores were significantly higher for treated wounds than for control wounds (2 vs 1).

**Conclusions and Clinical Relevance**—Bioactive glass in soft tissues does not cause a gross inflammatory reaction but causes an increase in histologic signs of inflammation, which decreases with time. Bioactive glass has potential for increasing tissue strength. Increased subcutaneous breaking strength could be beneficial in treating wounds in which early healing strength is needed. (*Am J Vet Res* 2001; 62:1149–1153)

Much of the work that has been done with bioactive glass (BG) to enhance healing has dealt with its use in bone for orthopedic and dental applications.<sup>1-4</sup> In these applications, the BG interacts with the osseous tissue to enhance healing. However, results of some

studies regarding use of BG in soft tissues indicate that it is nontoxic and does not cause adverse effects when implanted IM in rats and rabbits.<sup>5</sup> In another study, BG particles (diameter, 40 to 70  $\mu\text{m}$ ) administered SC in rats and guinea pigs caused no signs of inflammation or incompatibility.<sup>6</sup> Soft tissues may adhere to BG implants, with collagen playing a role in the attachment.<sup>2,5,7</sup> Implantation of BG in rats induces evidence of strong adhesion between the implant and connective tissue capsule that formed around them.<sup>5</sup> It has been suggested that direct chemical bonding between living and nonliving substances can take place, involving hydroxyapatite crystals, collagen, mucopolysaccharides, and glycoproteins.<sup>1</sup>

Phagocytosis by macrophages have been associated with BG implantation.<sup>3,5,6</sup> Phagocytosis has been reported for implant fragments<sup>7</sup> and for a particulate-grain form (40 to 70  $\mu\text{m}$ ) of BG.<sup>6</sup> In addition to phagocytic activity, macrophages have other functions in the wound healing process, including a regulatory function and production of growth factors, chemoattractants, cytokines, and proteolytic enzymes.<sup>8</sup> Macrophages synthesize and release substances that are known to stimulate migration and proliferation of fibroblasts.<sup>9</sup> For instance, transforming growth factor beta secreted by these cells results in fibroblast proliferation and collagen synthesis<sup>10</sup>; in addition, tumor necrosis factor alpha from macrophages enhances collagen deposition.<sup>11</sup> One of the major functions of fibroblasts is collagen production for wound strength.

It has been reported<sup>6</sup> that even distribution of a particulate-grain form of BG in soft tissues results in clusters of BG when examined after 2 weeks. By day 28, the BG particles are closely packed in clusters of different sizes and framed by several layers of tightly packed elongated connective tissue cells. At 49 days, the encapsulated clusters of BG are no longer detectable.

The purpose of the study reported here was to determine effects of intraincisional BG on healing of sutured skin wounds in dogs. Our hypothesis was that BG would enhance the healing of such wounds.

## Materials and Methods

**Animals**—The study was conducted under protocols approved by the Auburn University Institutional Animal Care and Use Committee. Nine purpose-bred mature female Beagles were used. The study was designed for 10 dogs; however, it was necessary to eliminate 1 dog for reasons unrelated to the study. Each dog served as its own control. Dogs were housed in a pen-run environment that had a grated floor and were allowed to acclimate to their environment for 7 days prior to beginning the study.

**Preoperative procedures**—Before anesthesia, each dog received atropine sulfate (0.4 mg/kg of body weight, IM) and

Received Mar 30, 2000.

Accepted Aug 3, 2000.

From the Wound Healing/Reconstructive Surgery Program, Scott-Ritchey Research Center (Gillette, Swaim, Bradley, Coolman), and the Department of Pathobiology (Sartin), College of Veterinary Medicine, Auburn University, Auburn, AL 36849. Dr. Gillette's present address is Sports Medicine Program, College of Veterinary Medicine, Auburn University, Auburn, AL 36849. Dr. Bradley's present address is Johnson & Johnson Wound Healing Technology Resource Center, 119 Grandview Rd, Skillman, NJ 08558.

Supported by US Biomaterials Corp, Alachua, Fla.

Presented as a poster at the Annual Symposium on Advanced Wound Care and Medical Research Forum on Wound Repair, Anaheim, Calif, Apr 24-27, 1999.

acetylpromazine (0.5 mg/kg, IM). General anesthesia was induced with thiopental (16 mg/kg, IV), and the dogs were intubated. After intubation, anesthesia was maintained with isoflurane (baseline, 2% in 30 ml of O<sub>2</sub>/kg/min). The dorso-lateral area of the trunk of each dog was clipped and scrubbed from the axillary region to the coxofemoral area for aseptic surgery.

**Surgery**—After draping, bilateral 3-cm full-thickness skin incisions were made 8 cm ventrolateral and parallel to the dorsal midline at the level of the 13th rib. The incisions extended through the cutaneous trunci muscle. Five centimeters cranial to these incisions, similar bilateral incisions were made that were 1 cm in length. Similar 1-cm incisions were made 4 cm ventral to each of these incisions.

Four simple interrupted sutures of 3-0 monofilament polypropylene<sup>a</sup> were preplaced in the two 3-cm wounds. The sutures included the skin and cutaneous trunci muscle. Digital pressure from a sterile gloved finger was applied to the wound for 3 minutes to ensure hemostasis. Any clot in the wound was gently removed with a cotton-tipped applicator to provide a wound surface free of blood clots and that contained a small amount of blood with which to mix the BG.

In 4 dogs, particulate BG (0.06 g; diameter, < 20 μm) was applied in the right wound and mixed into a slurry with the blood. The same procedures were used on the left wound; however, no BG was applied to the left wound. The two 1-cm wounds on each side of the dog were treated in the same manner; however, only 2 sutures were preplaced, and treated wounds received less BG (0.02 g; diameter, < 20 μm). Thus, wounds on the right side were treated wounds, and those on the left side were control wounds. In the remaining 5 dogs, wounds on the left side were treated, whereas wounds on the right side served as control wounds.

**Postoperative procedures**—Nonadherent semioclusive bandage pads<sup>b</sup> and a circumferential absorbent bandage wrap<sup>c</sup> were placed over all wounds; dressings extended from the folds of the flanks to the axillary regions. At the cranial edge of the bandage, a criss-cross arrangement of the wrap was made over the pectoral and shoulder areas to keep the bandage from slipping caudally. Porous adhesive tape<sup>d</sup> was placed as the outer bandage layer. Sidebar braces were incorporated into the tertiary bandage layer to prevent self-inflicted disturbance of the bandage or wound. Dressings were checked daily but were not removed until the third postoperative day, when wound perfusion was assessed.

**Subjective evaluations**—Wounds were evaluated subjectively throughout the study. The 3-cm wounds and dorsal 1-cm wounds were observed during the first 5 postoperative days for any grossly observable signs of inflammation. When these wounds were removed for breaking strength studies (3-cm wounds) and early histologic studies (dorsal 1-cm wounds), skin incisions to remove tissues were made through the skin and cutaneous trunci muscle in normal tissue adjacent to the wounds. Dissection of tissues was begun at the easily distinguishable plane beneath the cutaneous trunci muscle and carried toward the area under the incision. The plane continued under this area to the same plane on the other side of the incision. Following removal, the tissues underlying the skin incisions were subjectively observed for appearance of the tissue. Similar evaluations of the ventral 1-cm wound were made for 21 days, with assessment of the deeper tissues when the wound was removed for histological studies. All wounds that resulted from removing tissue for breaking strength and histologic studies were sutured and observed as they healed.

**Laser Doppler perfusion imaging**—A laser Doppler perfusion imager (LDPI)<sup>e</sup> and a corresponding computer

program<sup>f</sup> were used to scan the two 3-cm wounds at days 0, 3, and 5 to evaluate tissue perfusion as an indication of inflammation by recording the percentage of a laser beam reflected from moving cells (ie, blood cells in circulation) to provide a quantitative evaluation of tissue perfusion.

For this procedure, dogs were anesthetized as described and positioned in sternal recumbency. The LDPI was placed 7.5 cm above the wound. A consistent scan measurement area was used for all wounds at each time of recording. Each scan was taken using high resolution, a 6.1 threshold, and 0 (minimum) and 2 (maximum) perfusion settings. Objective data were obtained, using the LDPI version 2.4 software. The sum of the pixel values for the entire scan area around and including the closed wound was determined at each time of measurement. These sums were used to calculate the percentage of increase in perfusion at 3 and 5 days, compared with day-0 values.

**Breaking strength**—On the 5th postoperative day, the areas around the 3-cm wounds and dorsal 1-cm wound were prepared for aseptic surgery. A 2 × 5-cm segment of skin, subcutaneous tissue, and cutaneous trunci muscle were removed from the area of each 3-cm skin wound in such a way that the incision bisected the center of the segment across its short dimension. These segments were used for breaking strength studies of the wound tissues. To allow for accurate and secure placement of the tensiometer grips on the skin segments, all subcutaneous tissue and cutaneous trunci muscle were removed from the ends of the skin segment for a length of 1 cm. Each skin segment was wrapped in a sterile saline (0.9% NaCl) solution-moistened gauze until the segment was analyzed. The resulting defects were closed by use of a simple continuous 3-0 polydioxanone<sup>g</sup> subcutaneous suture and simple continuous skin sutures of 3-0 polypropylene.<sup>a</sup> The segments were taken immediately to the tensiometer<sup>h</sup> where they were affixed and placed under tension; breaking force was recorded in grams. Tension was applied to the samples, first noting the breaking strength of the skin, then the breaking strength of the underlying subcutaneous tissue and cutaneous trunci muscle at the same time of tension application.

**Histologic evaluation**—For histologic evaluation, the dorsal 1-cm wounds on both sides were used to assess the early (postoperative day 5) changes, and the ventral 1-cm wounds on both sides were used to assess the later (postoperative day 21) changes. Under general anesthesia, wounds on both sides were carefully prepared for aseptic surgery at the appropriate times. The 1-cm wounds were removed in a cubic block of tissue measuring 1 cm on a side, with the wound traversing the center of the block. The block included underlying subcutaneous tissue and cutaneous trunci muscle. The resulting defects were closed in the same manner used for closing defects resulting from obtaining samples for breaking strength studies.

These blocks of tissue were placed in neutral-buffered 10% formalin for fixation. The blocks containing the 1-cm wounds and underlying tissues were processed, stained with H&E, and evaluated for cellular infiltration (neutrophils, eosinophils, lymphocytes, plasma cells, macrophages, and mast cells) and other variables to evaluate inflammatory and reparative stages of healing. Edema, acute hemorrhage, chronic hemorrhage, necrosis, fibroblast infiltration, blood vessel proliferation, and collagen density were assessed. Each of these variables was assigned a score as follows: 0 = normal, 1 = mild increase, 2 = moderate increase, 3 = marked increase. Sparsely scattered neutrophils, lymphocytes, plasma cells, macrophages, eosinophils, and mast cells arranged in a random fashion in the tissues were considered normal. For each 400× magni-

fication field, localization of 3 to 10, 11 to 30, or  $\geq 31$  cells in the wound tissue was considered a mild, moderate, or marked increase, respectively.

Sparsely scattered necrotic cell debris, extravasated erythrocytes (indicative of acute hemorrhage), and hemosiderin-laden macrophages (indicative of chronic hemorrhage) were considered a mild increase for each of these variables. Focal dense accumulations of each of these components in the wound tissue were considered a moderate increase. Extensive tissue necrosis, massive hemorrhage that involved the surrounding tissue, and  $> 30$  hemosiderin-laden macrophages/400 $\times$  magnification field were considered a marked increase for each of these variables, respectively.

Fibroblasts and collagen organized in a random pattern, typical of normal dermis, were considered normal. For each 400 $\times$  magnification field, localization of fibroblasts and capillary buds in the wound tissue in numbers of 3 to 10, 11 to 30, and  $\geq 31$  were considered mild, moderate, and marked increase, respectively, for fibroblast proliferation and neovascularization. Scant collagen bundles slightly separating the fibroblasts in the wound tissues were considered a mild increase in collagen density. Somewhat dense accumulations of collagen between fibroblasts in the wound tissues were considered a moderate increase in collagen density. Extensive separation of collagen was considered a marked increase in collagen density.

Slight separation of cells and collagen from each other in the wound tissue by nonstaining or poorly staining acellular material was considered mild edema. Separation of approximately 30 to 50  $\mu\text{m}$  by this acellular material was considered moderate edema. Separation of  $> 50 \mu\text{m}$  was considered marked edema. All specimens were evaluated for 1 variable before proceeding to the next, which allowed for more accurate comparison of individual parameters.

**Statistical analyses**—Mean percentage increases in LDPI values for the BG-treated and control wounds were compared by use of a paired *t*-test at days 3 and 5. Differences between groups for suture line breaking strength were determined by use of a paired *t*-test. The Wilcoxon paired-sample test was used for data analysis of breaking strength of the subcutaneous tissues. The Wilcoxon paired-sample test was used to compare median scores of BG-treated and control wounds for each histologic variable. Differences between groups for all variables were considered significant at  $P < 0.05$ .

## Results

**Subjective evaluations**—When the sutures were tied, a small amount of blood-BG slurry overlying the apposed wound edges was detected. This formed a scab over the closed wound. Slight hyperemia was detected at the edges of all 3 BG-treated wounds on 1 dog, 3 days after surgery; this was not detected at 5 days, and the wounds progressed to heal well. On 1 other dog, the ventral 1-cm BG-treated wound and the 3-cm control wound appeared to have slight hyperemia at the wound edges at 3 days. As in the other dog, this was not detected at 5 days, and the wounds healed without complication. All wounds in the study healed without complications, gross signs of inflammation, or abscess formation.

In 2 wounds there was insufficient blood to form the slurry when the BG was mixed with the blood. One wound was a 3-cm wound and the other was a 1-cm wound. In these wounds, the BG-blood mixture had a putty consistency. At the time the 3-cm wound was removed at 5 days for breaking strength studies, a connective tissue capsule was clearly detected under half

of the wound's length. Bioactive glass appeared to be incorporated homogeneously into this capsule and was not in small clumps as in the subcutaneous tissue-cutaneous trunci area of other treated wounds. The skin of this wound had healed well without gross signs of inflammation. This wound had the greatest breaking strength for skin and next-to-greatest breaking strength for subcutaneous tissue-cutaneous trunci tissue at 5 days. Abnormal findings were not detected in the 1-cm wound when it was removed for histologic studies at 5 days.

In all treated wounds, with the exception of the wound in which the capsule formed, inspection of the subcutaneous tissue-cutaneous trunci muscle at the time of tissue removal revealed small clumps of material that was white-to cream-colored. These clumps were spherical to irregular in shape and were generally 2 to 3 mm in diameter. There were no gross signs of inflammatory reaction, tissue incompatibility, or abscess formation around these clumps.

**Perfusion**—Mean standard deviation percentage increase in perfusion of control and treated wounds from day 0 to day 3 was similar ( $75.4 \pm 60.2\%$  and  $77.9 \pm 43.6\%$ , respectively). At 5 days, mean percentage increase in perfusion, compared with day 0 values, had decreased in control ( $70 \pm 62.6\%$ ) and treated wounds ( $72.1 \pm 62.7\%$ ), compared with their 3-day values. There were no significant differences between treated and control wounds at days 3 or 5.

**Breaking strength**—There was no significant difference between treated (mean  $\pm$  SD,  $173.89 \pm 62.66$  g) and control wounds ( $154.58 \pm 59.17$  g) for breaking strength of the skin. Median  $\pm$  quartile deviation for breaking strength of subcutaneous tissue-cutaneous trunci tissues in the BG-treated wounds ( $188.75 \pm 64.38$  g) was significantly ( $P = 0.004$ ) greater than for control wounds ( $75.0 \pm 39.38$  g).

**Histologic evaluation**—There were significant differences between BG-treated wounds and control wounds in various median scores for histologic variables evaluated at 5 and 21 days. At 5 days, median (range) scores in BG-treated wounds were significantly greater for neutrophils (1 [0 to 3]), macrophages (2 [2 to 3]), and necrosis (1 [0 to 2]) than in control wounds for neutrophils (0 [0 to 1];  $P = 0.05$ ), macrophages (1 [0 to 1];  $P = 0.004$ ), and necrosis (0 [0 to 1];  $P = 0.02$ ). The macrophages that were present were multinucleated giant cells (Fig 1). No infectious organisms were detected in the wound tissues. At 21 days, the only significant difference between BG-treated and control wounds was a higher median score (range) for macrophages (2 [1 to 3] and 1 [0 to 2], respectively;  $P = 0.03$ ).

The clumps detected in the subcutaneous tissue-cutaneous trunci muscle area when tissues were harvested did not survive routine processing for histopathologic examination. Examination of the histologic sections revealed empty spaces surrounded by multinucleated giant cells. These spaces may have represented sites where the substance in the clumps (most likely BG) was dissolved during processing.



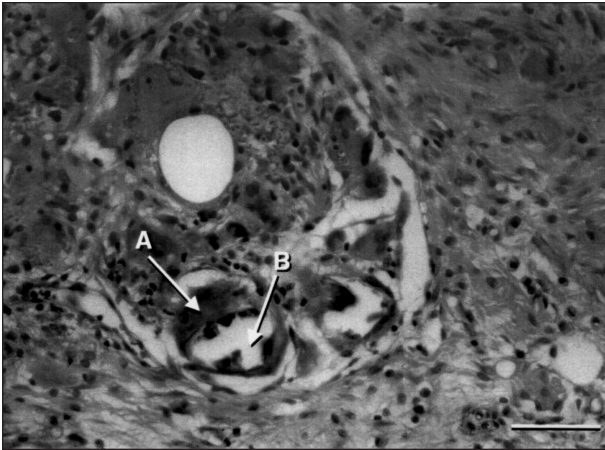


Figure 1—Photomicrograph of section of subcutaneous tissue from the area of an experimental skin wound treated with bioactive glass in a dog. Notice multinucleated giant cell (A) with a clear cytoplasmic region (B) likely associated with phagocytosis of bioactive glass. H&E stain; bar = 50  $\mu$ m.

## Discussion

The blood-BG slurry that was detected overlying the apposed wound edges when the sutures were tied was an indication that a small amount of slurry was interposed between the wound edges. Thus, most of the slurry was in the subcutaneous tissue with a smaller amount between the wound edges.

The absence of gross inflammation and abscesses in this study is consistent with the reported lack of toxicity, inflammation, and tissue incompatibility reported by others.<sup>5,6</sup> Although gram stains and bacteriologic cultures were not performed in this study, no infectious organisms were detected histologically in the tissues. The slight hyperemia that affected a small number of treated and control wounds may have been related to the bandage rubbing slightly on the wounds.

Wound perfusion, as revealed by use of LDPI, followed the pattern expected for progression of the inflammatory stage of wound healing in treated and control wounds. The values increased from day 0 to day 3 but began to decrease by day 5. The lack of significant differences between treated and control wounds for perfusion indicated the BG did not cause greater inflammation, compared with untreated wounds. This is in keeping with subjective observations and reports of others regarding lack of tissue reactivity.<sup>5,6</sup> The subcutaneous clumps of BG detected at 5 days in our study are in keeping with the clusters that have been reported by others.<sup>6</sup>

A study<sup>1</sup> investigating the bonding of BG with bone and soft tissue was performed with solid implants, and the results strongly suggest that direct chemical bonding between living and nonliving substances is possible. Results of study of compositional and microstructural variables indicate that the critical factors controlling direct chemical bonding *in vivo* are development of an alkaline pH at the surface of the implants, the time required for the surface to become alkaline, and surface-active calcium and phosphorus sites.<sup>1</sup>

The 3-cm wound in which the BG did not readily form a slurry but formed a subcutaneous putty-like

material developed a capsule. Disc implants in rats result in adhesion between the implant and the connective tissue capsule that forms around them.<sup>5</sup> The capsules require force to separate them from the implants, and tearing of the capsule suggests that the strength of the adhesion between the capsule and disc is stronger than the adhesions between fibers of the capsule. When BG implants are placed IM in rabbits, a cellular capsule of variable thickness composed of well vascularized fibrous tissue with variable amounts of macrophages develops at the implant surface at 9 to 12 days.<sup>5</sup> At 6 weeks, the fibrous capsule is relatively acellular and oriented parallel to the implant surface.<sup>5</sup> It is possible that capsule formation around the putty-like material in 1 dog in our study may have been a reaction similar to capsule formation around implants.

Movement and immobilization affect capsule formation and soft-tissue bonding. It has been stated that the consequence of movement is invariably a connective tissue capsule with the collagen fibers wrapped around the implant parallel to its surface, with variable cell numbers at the interface and the capsule. These cells produce numerous agents that maintain a fibrous response.<sup>7</sup> In muscle, continuous micromotion at the BG implant-tissue interface results in nonadherent fibrous capsules forming around the implants. However, when this implant-tissue interface is immobilized, collagen fibers of the soft tissue become embedded and bonded within the BG.<sup>2</sup> Our study did not investigate the effects of movement and immobilization on the influence of powdered BG on wound healing.

Given that collagen is the source of increased wound strength, the question arises regarding the source of the significantly higher breaking strength of the BG-treated subcutaneous tissue-cutaneous trunci tissue, because histologic scores for collagen density were not significantly different between BG-treated wounds and control wounds. Although collagen quantity may have been the same, it is possible that collagen quality differed between treated and control wounds. There is a possibility that BG-stimulated fibroblasts responded with early deposition of type-I collagen, which is a stronger collagen than the type-III collagen that is typically deposited in the early stages of healing. In an *in vitro* study<sup>12</sup> in which periodontal ligament fibroblasts were cultured with and without BG, procollagen type I production peaked at 11 days, and the amount of procollagen was greater in the presence of BG. It is possible that BG may have a similar effect *in vivo*. Because there may be direct chemical bonding between BG and living or nonliving substances,<sup>1</sup> it could also be theorized that such bonding took place in the tissues and resulted in stronger healing.

In our study, the concentration of BG was greatest in the subcutaneous tissue and cutaneous trunci muscle area. In addition, breaking strength of these tissue areas was significantly greater in BG-treated wounds, compared with control wounds.

Although there was some histologic evidence (significant increases in neutrophils, macrophages, and necrosis) of inflammatory reaction to BG in the early stage of healing (5 days), there were no gross signs of inflammation. Later, histologic assessment revealed

significantly greater numbers of macrophages in treated tissues, compared with control tissues, which correlates with the findings of others.<sup>5</sup>

On the basis on the information obtained in our study, we conclude that BG does not cause gross inflammation in soft tissues. Use of BG has potential for increasing tissue strength in soft tissues.

---

<sup>a</sup>Prolene, Ethicon, Somerville, NJ.

<sup>b</sup>Telfa adhesive pads, Kendall Healthcare Products Co, Mansfield, Mass.

<sup>c</sup>Sof-Band bulky bandage, Johnson & Johnson Products Inc, Arlington, Tex.

<sup>d</sup>Zonas porous adhesive tape, Johnson & Johnson Products Inc, Arlington, Tex.

<sup>e</sup>Laser Doppler perfusion imaging, Licsa Development AB, Linköping, Sweden.

<sup>f</sup>LDI Version 2.4, Licsa Development AB, Linköping, Sweden.

<sup>g</sup>PDS, Ethicon, Somerville, NJ.

<sup>h</sup>Instron Model 1011, Canton, Mass.

---

## References

1. Hench LL, Paschall HA. Direct chemical bond of bioactive glass-ceramic materials to bone and muscle. *J Biomed Mater Res Symp* 1973;4:25–42.
2. Hench LL. Bioactive glasses and glass-ceramics: a perspective. In: Yamamuro T, Hench LL, Wilson J, eds. *CRC Handbook of bioactive ceramics, vol. I, bioactive glasses and glass-ceramics*. Boston: CRC Press, 1990;7–23.
3. Wilson J, Low S, Fetner A, et al. Bioactive materials for periodontal treatment: a comparative study, in *Proceedings*. 6th Euro Conf Biomat, Bologna, Italy, 1986;223–228.
4. Ousterhout DK, Stelnicki EJ. Plastic surgery's plastics. *Clin Plast Surg* 1996;23:183–190.
5. Wilson J, Piggot GH, Schoen FJ, et al. Toxicology and biocompatibility of bioglasses. *J Biomed Mater Res* 1981;15:805–817.
6. Pohunková H, Adam M. Reactivity and the fate of some composite bioimplants based on collagen in connective tissue. *Biomaterials* 1995;16:67–71.
7. Wilson J, Nolletti D. Bonding of soft tissues to bioactive glass. In: Yamamuro T, Hench LL, Wilson J, eds. *CRC Handbook of bioactive ceramics, vol. I, bioactive glasses and glass-ceramics*. Boston: CRC Press, 1990;283–302.
8. Swaim SF, Vaughn DM, Kincaid SA, et al. Effect of locally injected medications on healing of pad wounds in dogs. *Am J Vet Res* 1996;57:394–399.
9. Häkkinen L. Fibroblast-bioactive glass interactions. In: Yamamuro T, Hench LL, Wilson J, eds. *CRC Handbook of bioactive ceramics, vol. I, bioactive glasses and glass-ceramics*. Boston: CRC Press, 1990;235–244.
10. Swaim SF, Henderson RA. In: *Small animal wound management*. Baltimore: The Williams & Wilkins Co, 1997;1–12.
11. Barbul A. Factors affecting tissue repair: role of the immune system. In: Cohen IK, Diegelmann RD, Linblad WJ, eds. *Wound healing: biochemical and clinical aspects*. Philadelphia: WB Saunders Co, 1992;282–291.
12. Kubo K, Tsukasa N, Uehara M, et al. Calcium and silicon from bioactive glass concerned with formation of nodules in periodontal-ligament fibroblasts in-vitro. *J Oral Rehabil* 1997;24:70–75.