

# Prokinetic effects of erythromycin on the ileum, cecum, and pelvic flexure of horses during the postoperative period

Allen J. Roussel, DVM, MS; R. Neil Hooper, DVM, MS; Noah D. Cohen, VMD, PhD; Alicia D. Bye, DVM; Russell J. Hicks, DVM; Tonya W. Bohl, BS

**Objective**—To evaluate the effect of erythromycin on motility of the ileum, cecum, and pelvic flexure of horses during the postoperative and post-recovery periods.

**Animals**—8 healthy adult horses.

**Procedure**—Horses were anesthetized and bipolar electrodes were implanted in smooth muscle of the ileum, cecum, and pelvic flexure. Approximately 4, 16, and 24 hours (postoperative recording sessions) and at least 8 days (post-recovery recording session) after surgery, myoelectric activity was recorded before and after administration of erythromycin (0.5 mg/kg).

**Results**—Following erythromycin administration, myoelectric activity was increased in the ileum during all postoperative recording sessions but not during the post-recovery recording session. Myoelectric activity was increased in the cecum following erythromycin administration only during the post-recovery recording session. Myoelectric activity was increased in the pelvic flexure following erythromycin administration during all recording sessions. During several recording sessions, there were short periods during which myoelectric activity was significantly decreased following erythromycin administration.

**Conclusions and Clinical Relevance**—Results suggest that erythromycin has an effect on myoelectric activity of the ileum, cecum, and pelvic flexure in horses; however, prokinetic effects of erythromycin administered during the postoperative period were not always the same as effects obtained when the drug was administered after horses had recovered from the effects of surgical implantation of recording devices. Therefore, caution must be exercised when extrapolating results of prokinetic studies in healthy animals to animals with abnormal gastrointestinal tract motility. (*Am J Vet Res* 2000;61:420–424)

Prokinetic effects of erythromycin, a macrolide antibiotic, have been characterized in people, dogs, and rabbits in vivo and in vitro.<sup>1-3</sup> One mechanism by which macrolide antibiotics exert their prokinetic effects is thought to be stimulation of motilin receptors.<sup>4</sup> Motilin

Received Oct 19, 1998.

Accepted Jun 7, 1999.

From the Department of Large Animal Medicine and Surgery, College of Veterinary Medicine, Texas A&M University, College Station TX 77843-4475. Dr. Bye's present address is Westbury Animal Hospital Inc, 4917 S Willow Dr, Houston, TX 77035. Dr. Hicks' present address is Bandera Vet Clinic, PO Box 1629, Bandera, TX 78003. Ms. Bohl's present address is Rte 3, Box 235-B, Hamilton, TX 76531.

The authors thank Dr. Gwendolyn Carroll for technical assistance. Erythromycin was donated by Abbott Laboratories, North Chicago, IL 60064. Amikacin was donated by Fort Dodge Laboratories, Fort Dodge, IA 50501.

is a hormone that initiates contractile activity by binding to specific receptors on smooth muscle cells. In dogs, an alternative mechanism of action of macrolide antibiotics that possibly involves stimulation of cholinergic receptors has been demonstrated.<sup>5</sup>

The prokinetic effects of the macrolide antibiotics are most consistent among species and of greatest intensity in the stomach and proximal part of the small intestine.<sup>1,2</sup> In rabbits, response of the gastrointestinal tract to motilin decreases in an aboral direction,<sup>6</sup> and it is unclear whether erythromycin has an effect on large intestinal motility.<sup>7,a,b</sup> In horses, IV administration of erythromycin accelerates gastric emptying and causes spiking activity in the colon.<sup>8,a,c</sup> It also decreases emptying time of and increases the spike burst rate and duration in the cecum and right ventral colon of healthy horses.<sup>9</sup>

Postoperative ileus is an important life-threatening complication of abdominal surgery of horses. Several prokinetic drugs have been recommended for treatment of postoperative ileus, but few have been evaluated in horses with naturally occurring or experimentally induced ileus.<sup>10,d</sup> Coatney et al<sup>d</sup> found that IV infusion of motilin caused an increase in ileal and jejunal myoelectric and myomechanical activity in horses with experimentally induced postoperative ileus. However, previous studies of the effects of erythromycin on gastrointestinal motility in horses have involved healthy horses that were allowed to recover from the effects of surgical implantation of recording devices before changes in gastrointestinal motility were measured. The purpose of the study reported here was to evaluate the effect of erythromycin on motility of the ileum, cecum, and pelvic flexure of horses during the postoperative and post-recovery periods.

## Materials and Methods

The experimental protocol was reviewed and approved by the University Laboratory Animal Care Committee. Seven mature geldings and 1 mare (4 Thoroughbreds and 4 Quarter Horses) weighing between 461 and 547 kg were used. Feed and water was withheld for 24 hours, and horses were then anesthetized with xylazine hydrochloride (1.1 mg/kg of body weight, IV), diazepam (2.2 mg/kg, IV), and ketamine hydrochloride (0.015 mg/kg, IV). Anesthesia was maintained with sevoflurane (3.5 to 5.5%) in oxygen. A ventral midline celiotomy was performed, and 16 bipolar electrodes were introduced into the smooth muscle of the ileum, cecum, and pelvic flexure. The electrodes were constructed of 22-gauge silver wire<sup>e</sup> and 26-gauge silver-coated copper wire<sup>f</sup> embedded in polymethyl methacrylate acrylic.<sup>g</sup> They were sterilized before surgery with a hydrogen peroxide-based gas sterilization system.<sup>h</sup> Four of the bipolar electrodes were inserted in smooth muscle of the ileum and sutured to the serosa with

2-0 polydioxanone.<sup>l</sup> Electrodes were placed at 5-cm intervals along the antimesenteric border of the ileum, beginning at the termination of the ileocecal ligament on the ileum and continuing aborad. Six of the bipolar electrodes were inserted in smooth muscle of the cecum between the dorsal and medial cecal bands and sutured to the serosa. The first electrode was sutured at the apex of the cecum and the last as close to the base as possible. The other 4 electrodes were equally spaced between the first and last cecal electrodes. The remaining 6 bipolar electrodes were inserted in smooth muscle of the pelvic flexure and sutured to the serosa at 5-cm intervals beginning 12.5 cm orad and ending 12.5 cm aborad to the termination of the left lateral band of the left ventral colon. The free ends of the wires were passed through the abdominal wall and tunneled subcutaneously approximately 20 cm to exit the skin 10 cm cranial to the incision. Prong connectors were soldered to the ends of the electrode wires and inserted in a 37-hole plug adaptor.<sup>l</sup> During surgery, a 100-cm segment of jejunum between 300 and 400 cm orad to the ileojejunal junction was rubbed vigorously with dry gauze sponges 100 times and then wrapped in a dry towel for 30 minutes to mimic trauma induced by surgical intervention in the abdomen. Total surgery time ranged from 3 to 4 hours.

Amikacin (16 mg/kg) or gentamicin (6.6 mg/kg) was administered IV immediately prior to surgery and once daily for 4 to 5 days after surgery. Five horses also received metronidazole (10 mg/kg, PO, q 12 h) for 3 to 10 days after surgery. Horses were allowed water immediately after surgery but were not given grain or hay until approximately 28 hours after surgery, at which time they were offered small amounts of hay and grain. Over the next few days, horses were gradually returned to their regular ration, which consisted of free-choice coastal Bermuda grass hay and grain mix twice daily.

Myoelectric activity of the ileum, cecum, and pelvic flexure was recorded 4 times after surgery. The first recording session was begun 2 hours after horses had recovered sufficiently from anesthesia that they were able to stand and lasted for 4 hours. After the first 2 hours of the recording session, erythromycin lactobionate (0.5 mg/kg) was administered IV as a bolus over 1 minute by means of jugular venipuncture, and recording was continued for an additional 2 hours. The second and third recording sessions took place the day after surgical implantation of the electrodes. Each session lasted 6

hours, and sessions were separated by a 30-minute break. Three hours into each session, erythromycin was administered, and recording was continued for an additional 3 hours. Horses were not offered any grain or hay until after the third recording session. The fourth recording session took place at least 8 days after implantation of the electrodes and at least 7 days after cessation of diarrhea in affected horses. This session also lasted for 6 hours, and 3 hours into the session, erythromycin was administered. Horses were not given any grain the morning of the fourth recording session but had ad libitum access to hay throughout this session. Horses were used in several other studies while the electrodes were functioning and were euthanized at the conclusion of all studies (approx 12 weeks after surgery).

Myoelectric activity was recorded by use of a data acquisition software package.<sup>k</sup> Data were stored on disks<sup>l</sup> until analyzed. The recordings were observed visually for **migrating myoelectric complexes (MMC)** in the ileum and **slow moving complexes (SMC)** and **colonic migrating myoelectric complexes (CMMC)** in the pelvic flexure. Phase 3 of the MMC in the ileum was defined as the period during which there was intense spiking activity superimposed on virtually all slow waves. All segments of ileal recordings that contained phase-3 activity were eliminated from analysis; the proportion of segments eliminated for this reason ranged from 3 to 52%. The cecum did not have any electrical activity during the first recording session; therefore, it was not included in analyses of that session.

Digitized myoelectric signals for each of the channels were processed by use of computer software<sup>m</sup> prior to analysis. The signal was rectified, and the baseline was then adjusted to eliminate electrical noise. Signals were integrated in 5-second intervals, and these values were downloaded to a spreadsheet and summed in 5-minute segments to obtain activity indices. Time of administration of erythromycin was designated time 0, and activity indices for the first 15 minutes after erythromycin administration (divided into three 5-minute segments) and for the first hour after erythromycin administration (divided into four 15-minute segments) were analyzed.

**Data analyses**—Data were analyzed separately for the ileum, cecum, and pelvic flexure. For the three 5-minute seg-

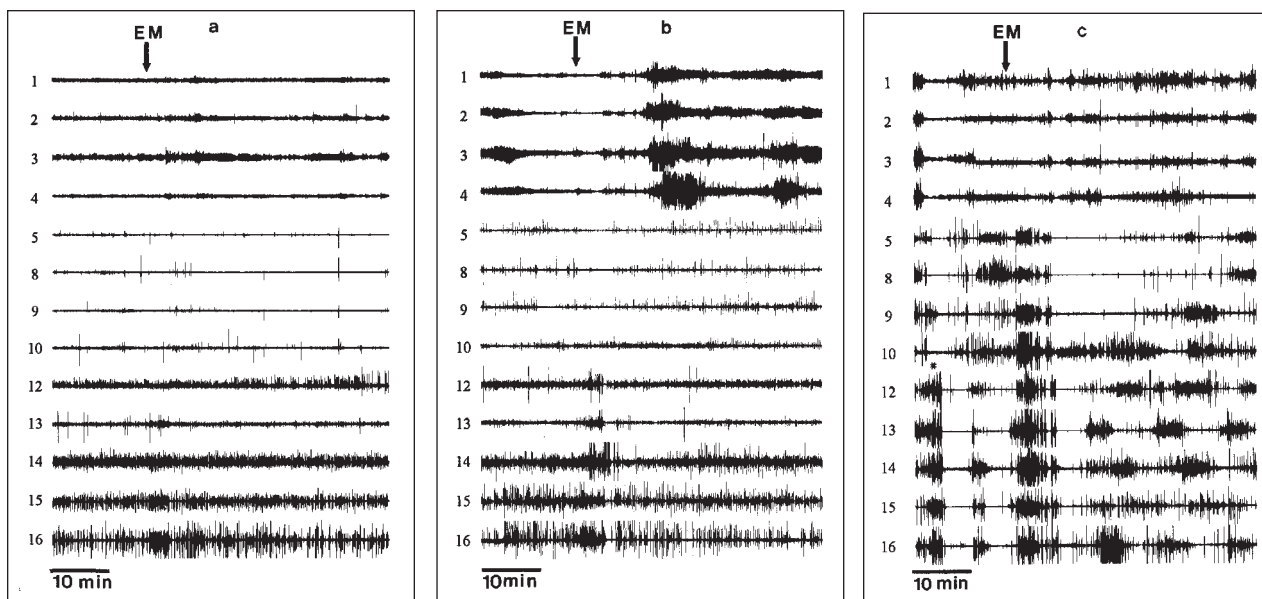


Figure 1—Representative tracings of myoelectric activity of the ileum (lanes 1 through 4), cecum (lanes 5, 8, 9, and 10), and pelvic flexure (lanes 12 through 16) of a horse approximately 4 hours (a), 24 hours (b), and 8 days (c) after implantation of recording electrodes. Arrow indicates time of administration of erythromycin (EM; 0.5 mg/kg). \* = Spontaneous colonic migrating electric complex.

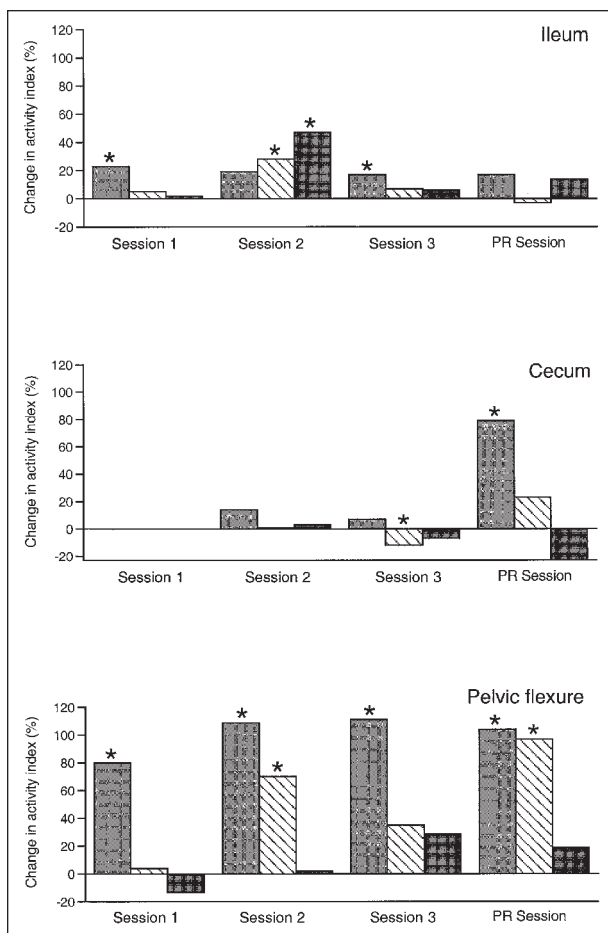


Figure 2—Mean percentage change in index of myoelectric activity of the ileum, cecum, and pelvic flexure of 8 horses during three 5-minute segments (□, ▨, and ■) immediately after administration of erythromycin (0.5 mg/kg), compared with activity before erythromycin administration. Activity was recorded shortly after horses recovered from anesthesia for surgical implantation of recording electrodes (session 1), the morning (session 2) and afternoon (session 3) of the following day, and approximately 8 days later (post-recovery [PR] session). \* =  $P < 0.05$ .

ments immediately following erythromycin administration, activity indices were divided by one-third the activity index for the 15-minute period immediately before erythromycin administration to obtain percentage change in activity index. For the four 15-minute segments immediately following erythromycin administration, activity indices were divided by the activity index for the 15-minute period immediately before erythromycin administration to obtain percentage change in activity index.

Percentage changes in activity indices were compared by use of a generalized linear models approach with horses modeled as random effects, electrodes modeled as fixed effects nested within horses, and time periods modeled as fixed effects.<sup>11</sup> The Duncan multiple range test was used to analyze differences between periods.<sup>11</sup> A value of  $P \leq 0.05$  was considered significant.

## Results

A few horses had mild, transient signs of abdominal discomfort, including pawing, treading of the hind feet, and looking at the flank immediately following injection of erythromycin and lasting no longer than 5 minutes. Phase-3 activity was identified in recordings of myoelec-

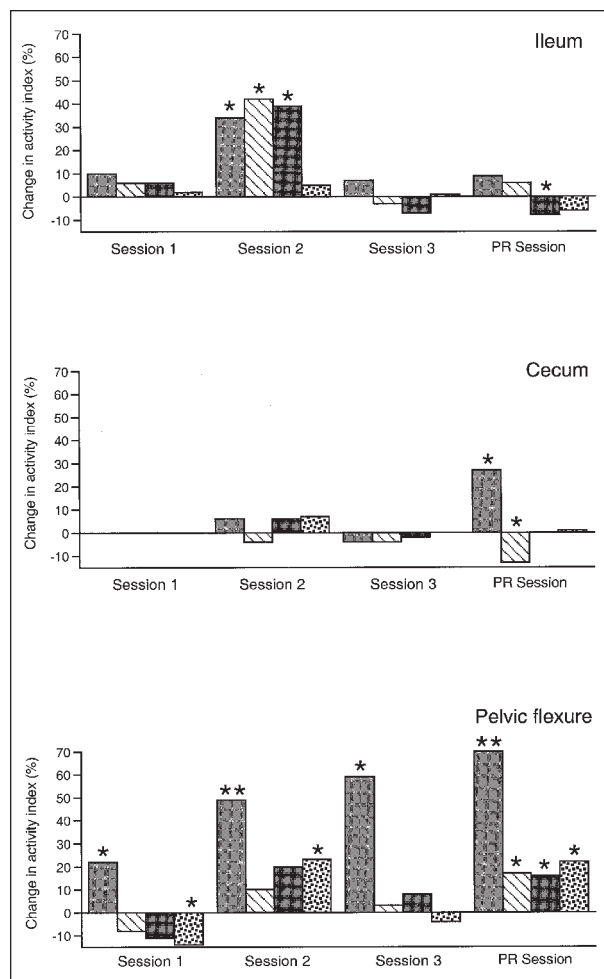


Figure 3—Mean percentage change in index of myoelectric activity of the ileum, cecum, and pelvic flexure of 8 horses during four 15-minute segments (□, ▨, ▩, and ■) immediately after administration of erythromycin, compared with activity before erythromycin administration. See Figure 2 for key. \*\* =  $P < 0.001$ .

tric activity of the ileum in 6 of 8 horses during the first recording session and in 7 of 8 horses during the second recording session and in all horses during subsequent sessions. The horse in which phase-3 activity was absent during the second recording session had phase-3 activity during the first recording session. Recognizable CMMC were identified in 2 horses during the first recording session, 4 horses during the second recording session, and 2 horses during the third recording session. Recognizable SMC were not identified in any of the horses during the first recording session but were identified in 4 horses during the second recording session and in 7 horses during the third recording session. During the post-recovery period (ie, the fourth recording session), SMC were identified in all horses. Visual inspection of recordings of myoelectric activity suggested that the ileum, cecum, and pelvic flexure were all less active during the first recording session than during the post-recovery period (Fig 1), and the relative difference in activity between the first recording session and the post-recovery period appeared to be greater for the cecum than for the ileum or pelvic flexure. In addition, overall activity in each region appeared visually to be greater during the post-

recovery period than during the postoperative period (first, second, and third recording sessions).

**Postoperative period**—When activity indices for the three 5-minute segments after erythromycin administration were analyzed, significant increases in activity indices of the ileum and pelvic flexure were found during 1 or 2 segments of each of the 3 postoperative recording sessions (Fig 2). Activity indices of the cecum were not significantly increased during any of the 5-minute segments after erythromycin administration in the 3 postoperative recording sessions. In fact, a significant decrease in activity index was recorded for 1 segment of the third recording session.

When activity indices for the four 15-minute segments after erythromycin administration were analyzed, significant increases in activity indices of the ileum were detected during the second recording session (Fig 3). Activity indices of the pelvic flexure were significantly increased during 1 or 2 segments of each of the 3 postoperative recording sessions; however, activity index of the pelvic flexure was significantly decreased during the fourth segment of the first recording session. Activity index of the cecum was not significantly changed after erythromycin administration during any of the 3 postoperative recording sessions.

**Post-recovery period**—When activity indices for the three 5-minute segments after erythromycin administration were analyzed, significant increases in activity indices of the cecum and pelvic flexure were detected during 1 or 2 segments of the post-recovery recording session (Fig 2). Activity index of the ileum was not significantly increased after erythromycin administration during the post-recovery recording session.

When activity indices for the four 15-minute segments after erythromycin administration were analyzed, a significant decrease in activity index of the ileum was detected during 1 segment of the post-recovery recording session (Fig 3). Activity index of the cecum was significantly increased during the first segment of this recording session, but significantly decreased during the second. Activity index of the pelvic flexure was significantly increased during all 4 segments of the post-recovery recording session.

During the postoperative and post-recovery recording sessions, visual inspection of the tracings of myoelectric activity revealed a typical response to erythromycin injection. Beginning within 30 seconds after erythromycin administration and persisting for 5 to 10 minutes, intense spiking was evident. This period of spiking was followed by a period of relative quiescence for 1 to 5 minutes. This response was most consistent and most intense in the cecum.

## Discussion

The protocol for inducing postoperative ileus in the present study was similar to that of Gerring and Hunt,<sup>12</sup> except that ileus was induced at the time of implantation of the electrodes, which obviated the need for a second surgery. This protocol did not result in clinical ileus in that horses did not have any signs of abdominal pain or gastrointestinal reflux and were able to eat soon after surgery. However, for all 3 regions of

the intestine studied, recordings of myoelectric activity obtained during the postoperative period were quite different from recordings obtained during the post-recovery period. The postoperative period was characterized by absence of myoelectric activity or a reduction in the amplitude of the myoelectric activity, compared with normal, and apparently reduced, spiking activity.

There were probably several factors, including anesthesia, implantation of the electrodes, local reaction around the electrodes, and intentional surgical trauma, that contributed to postoperative hypomotility of the intestinal tract in these horses. Anesthetic regimens similar to those used in the present study reduced myoelectric activity in the ileum, cecum, and colon of horses—but for no more than 9 hours.<sup>13</sup> Therefore, anesthesia probably had an effect on recordings obtained during the first postoperative recording session, but any anesthetic effects should have dissipated by the second recording session. Unfortunately, the present study was not designed to differentiate among the various factors that can contribute to hypomotility of the gastrointestinal tract in horses. However, the study was designed to mimic the clinical situation in which several factors probably combine to cause postoperative ileus in horses undergoing surgery for colic. The cecum had essentially no myoelectric activity during the first recording session and had relatively less activity during the second and third recording sessions, compared with the post-recovery recording session. Therefore, we believe that responses obtained in this study were similar to those that could be expected in horses with naturally occurring postoperative ileus. At the very least, the protocol used in the present study was superior to protocols used in previous studies in which recordings were obtained only during the post-recovery period, especially when used to evaluate possible interventions for postoperative ileus.

In the present study, recovery of motility in the cecum was prolonged relative to recovery of activity in the ileum and pelvic flexure. This lag may predispose horses to impaction or delayed cecal emptying during the early postoperative period; however, the extent to which decreased cecal motility contributes to increased incidence of ileus and other abnormalities of gastrointestinal motility during the postoperative period remains unknown. Furthermore, although there was no change in myoelectric activity of the cecum following erythromycin administration in the postoperative periods (first, second, and third recording sessions), there was a significant increase in activity in response to erythromycin administration during the post-recovery period (fourth recording session). This suggests that results of studies of the prokinetic effects of drugs conducted during the post-recovery period in clinically normal horses should not be generalized to horses with abnormal gastrointestinal tract motility, including horses with postoperative ileus. Moreover, results of this study indicated that erythromycin and, possibly, other drugs that have prokinetic effects on the gastrointestinal tract may provide little clinical benefit when used to restore cecal motor activity. Whenever possible, drugs intended for treatment of ileus should be evaluated in horses with naturally occurring or experimentally induced ileus.

The study was originally designed to determine

effects of erythromycin for up to 7 recording sessions over 4 days following implantation of electrodes. However, only results for the first 3 postoperative sessions were used. First, by the third recording session, patterns of myoelectric activity were returning to those usually observed in the post-recovery period. Second, a few horses developed diarrhea on postoperative day 3.

The cause of diarrhea in the horses used in this study was not determined. Attempts to isolate salmonellae and clostridia were unsuccessful. The diarrhea could have been caused by the post-operative treatment regimen, including erythromycin administration, coupled with the stress of surgery. Diarrhea has been described anecdotally as a complication of erythromycin treatment in horses.<sup>14</sup> The potential for development of diarrhea has prevented some veterinarians from using erythromycin as a prokinetic drug in horses. However, problems associated with diarrhea may soon be eliminated, as pharmaceutical companies develop macrolide drugs with prokinetic, but not antibiotic, properties. Further studies are needed to investigate the potential association between erythromycin administration and development of diarrhea in horses administered multiple small doses of the drug.

The magnitude of increase in myoelectric activity following erythromycin administration was greater in the pelvic flexure than in the ileum and cecum, particularly during the postoperative period. This suggests that erythromycin may be most useful for treatment of hypomotility of the colon, rather than the ileum and cecum.

The ileum is less responsive to erythromycin *in vitro* and *in vivo* than are the more proximal parts of the small intestine,<sup>5,6</sup> and in a previous study,<sup>9</sup> there was no difference in spike burst rate or duration or in activity index in ileum following administration of erythromycin to horses. In the present study, however, increased activity of the ileum in response to erythromycin administration was detected during the first three 15-minute segments of the second recording session; whereas, similar increases were not detected during the third recording session. During the post-recovery recording session, there was a slight decrease in activity in the ileum in the third 15-minute segment. Evaluation and interpretation of data for the ileum were complicated by the natural occurrence of phase-3 activity, which was particularly common during the third and the post-recovery recording sessions. About half the segments from these sessions were eliminated because of phase-3 activity.

During several sessions, there were segments during which myoelectric activity was significantly decreased following erythromycin administration, although the magnitude of the decrease was generally small. The mechanism of this apparent inhibition is unknown, as is the clinical relevance of this phenomenon. The period of quiescence is not likely beneficial, but it may have a minimal negative effect on the overall prokinetic effect of erythromycin, because inhibition was relatively short-lived. Although myoelectric activity is well-correlated with contractile activity, it is not always directly correlated with flow of ingesta. Therefore, if substantial flow occurs during stimulation, the period of decreased activity may be insignificant.

In conclusion, results of this study suggest that in

horses, the prokinetic effects of erythromycin administered during the postoperative period are not always the same as effects obtained when the drug is administered to healthy horses. Therefore, caution must be exercised when extrapolating results of prokinetic studies carried out in healthy animals to animals with abnormal gastrointestinal tract motility.

<sup>a</sup>Masri MD, Merritt AM, Burrow JA. Effect of erythromycin on equine colonic motility (abstr), in *Proceedings. Am Motil Soc 6th Biennial Meet*, 1990;113.

<sup>b</sup>Hasler WL, Heldsinger A, Soudah H, et al. Erythromycin promotes colonic transit in humans: mediation via motilin receptors (abstr). *Gastroenterology* 1990;98:A358.

<sup>c</sup>Lester GD. The effect of drugs on cecal motility (abstr), in *Proceedings. 14th Annu Meet Vet Med Forum* 1996;736.

<sup>d</sup>Coatney RW, Adams SB. The effect of motilin on equine small intestinal motility during experimental postoperative ileus (abstr), in *Proceedings. 3rd Equine Colic Res Symp* 1988;12.

<sup>e</sup>HB Hagstanz & Sons Inc, Chicago, Ill.

<sup>f</sup>Alpha Wire Corp, Elizabeth, NJ.

<sup>g</sup>Ortho-jet acrylic, Henry Schein, Port Washington, NY.

<sup>h</sup>Sterrad, Advanced Sterilization Products, Irvine, Calif.

<sup>i</sup>PDS, Ethicon, Johnson & Johnson, Somerville, NJ.

<sup>j</sup>Parts No. 40-137FHS, 40-137P, 40-101, 40-102, AMP, Harrisburg, Pa.

<sup>k</sup>WINDAQ 200, Dataq Instruments Inc, Akron, Ohio.

<sup>l</sup>Omega Zip Discs, Omega Corp, Roy, Utah.

<sup>m</sup>WINDAQ Playback, Dataq Instruments Inc, Akron, Ohio.

## References

- Otterson MF, Sarna SK. Gastrointestinal motor effects of erythromycin. *Am J Physiol* 1990;259:G355-G363.
- Sarna SK, Soergel KH, Koch TR, et al. Gastrointestinal motor effects of erythromycin in humans. *Gastroenterology* 1991;101:1488-1496.
- Marzio L, Grossi L, Martelli L, et al. Migrating motor complex recorded spontaneously and induced by motilin and erythromycin in an *ex vivo* rabbit intestinal preparation. *Peptides* 1994;15:1067-1077.
- Peeters T, Matthijs G, Depoortere I, et al. Erythromycin is a motilin receptor agonist. *Am J Physiol* 1989;257:G470-G474.
- Qin XY, Pilot MA, Thompson H, et al. Effects of cholinergic receptor and 5-hydroxytryptamine<sub>3</sub> receptor antagonism on erythromycin-induced canine intestinal motility disruption and emesis. *Br J Pharmacol* 1993;108:44-49.
- Depoortere I, Peeters TL, Vantrappen G. Development of motilin receptors and of motilin- and erythromycin-induced contractility in rabbits. *Gastroenterology* 1990;99:652-658.
- Jameson JS, Rogers J, Misiewicz JJ, et al. Oral or intravenous erythromycin has no effect on human distal colonic motility. *Aliment Pharmacol Ther* 1992;6:589-595.
- Ringger NC, Lester GD, Neuwirth L, et al. Effect of bethanechol or erythromycin on gastric emptying in horses. *Am J Vet Res* 1996;57:1771-1775.
- Lester GD, Merritt AM, Neuwirth L, et al. Effect of erythromycin lactobionate on myoelectric activity of ileum, cecum, and right ventral colon, and cecal emptying of radiolabeled markers in clinically normal ponies. *Am J Vet Res* 1998;59:328-334.
- Gerring EEL, King JN. Cisapride in the prophylaxis of equine post operative ileus. *Equine Vet J* 1989;7(Suppl):52-55.
- Little RC, Freund RJ, Spector PC. SAS systems for linear models. 3rd ed. Cary, NC: SAS Institute Inc, 1991.
- Gerring EEL, Hunt JM. Pathophysiology of equine postoperative ileus: effect of adrenergic blockade, parasympathetic stimulation and metoclopramide in an experimental model. *Equine Vet J* 1986;18:249-255.
- Lester GD, Bolton JR, Cullen LK, et al. Effects of general anesthesia on myoelectric activity of the intestine in horses. *Am J Vet Res* 1992;53:1553-1557.
- Gustafsson A, Baverud V, Gunnarson A, et al. The association of erythromycin ethylsuccinate with acute colitis in horses in Sweden. *Equine Vet J* 1997;29:314-318.